

NATIONAL COLPOSCOPY TRAINING MODULE, GUIDELINE AND STANDARD OPERATING PROCEDURE

**NATIONAL CANCER CONTROL PROGRAMME
MINISTRY OF HEALTH AND INDIGENOUS MEDICAL SERVICES
SRI LANKA**

(The technical contents of this book was adopted from the
WORLD HEALTH ORGANIZATION PUBLICATION
'TRAINING OF HEALTH STAFF IN COLPOSCOPY, LEEP AND CKC – TRAINEES'
HANDBOOK' – ISBN 978-92-9022-556-0)

National Colposcopy Training Module, Guideline and Standard Operating Procedure

First Edition – JULY 2020

© **National Cancer Control Programme**

ISBN 978-955-3666-84-0

Ministry of Health & Indigenous Medical Services

Public Health Complex,
No. 555/5, Elvitigala Mawatha,
Colombo 05,
Sri Lanka.
Tel : +94 11 2368627

Suggested Citation :

National Colposcopy Training Module, Guideline and Standard Operating Procedure. National Cancer Control Programme, Ministry of Health & Indigenous Medical services, Colombo, Sri Lanka ; 2020.

*Electronic version is available on www.nccp.health.gov.lk

Printed by : Nanila Publication (Pvt) Ltd.
No. 227/30, Nirmana Mawatha,
Nawala Road, Nugegoda.
Tel : +94 11 4809400

LIST OF CONTRIBUTORS

1. Dr. Samanthi Premaratne	Consultant Gynaecologist, Apeksha Hospital
2. Dr. Chintana Hapuarachchi	Consultant Gynaecologist, Apeksha Hospital
3. Dr. Sarada Kannangara	Consultant Gynaecologist, Apeksha Hospital
4. Dr. Nayana De Alwis	Consultant Community Physician, National Cancer Control Programme
5. Dr. Ruwan Silva	Consultant VOG, Family Health Bureau
6. Dr. Athula Fernando	Consultant VOG, DGH Negombo
7. Dr. Bathiya Alagoda	Consultant Gynaecologist, TH Kandy
8. Dr. L. Ransiri	Consultant VOG, DGH Gampaha
9. Dr. Himali Perera	Consultant Venereologist, National STD/AIDS Control Programme
10. Dr. Chandrika Jayakody	Consultant Venereologist, National STD/AIDS Control Programme
11. Dr. Nilmini Hemachandra	Consultant Community Physician, National Programme Officer, World Health Organization
12. Dr. Loshan Moonesinghe	Consultant Community Physician, Family Health Bureau
13. Dr. Virginie Mallawaarchchi	Consultant Community Physician, National Programme Officer, World Health Organization
14. Dr. Prasanna Gunasekera	Consultant VOG

COORDINATING COMMITTEE

Dr. Janaki Vidanapathirana	Director, National Cancer Control Programme
Dr. Sudath Samaraweera	Former Director, National Cancer Control Programme
Dr. Suraj Perera	Consultant Community Physician, National Cancer Control Programme
Dr. Priyantha Wijesinghe	Deputy Director, National Cancer Control Programme
Dr. Usha Jayasooriya	Former Deputy Director, National Cancer Control Programme
Dr. T. A. Wickramatunga	Medical Officer, National Cancer Control Programme
Dr. W.M.S. Weerakoon	Registrar in Community Medicine, National Cancer Control Programme
Dr. Kalpanie Wijewardana	Medical Officer, National Cancer Control Programme
Dr. Asanga Hemarathna	Medical Officer, National Cancer Control Programme
Dr. Dulanjali Laxamana	Medical Officer, National Cancer Control Programme
Dr. Nirmala Jayanthi	RMO, National Cancer Control Programme
Mrs. Malani Basnayake	Special Grade Nursing Officer, National Cancer Control Programme

CONTENTS

FOREWORD vii

EXECUTIVE SUMMARYviii

LIST OF ABBREVIATIONS ix

1 INTRODUCTION 01

2 PATHOPHYSIOLOGY OF CERVICAL PRE-CANCEROUS LESION AND CANCER 07

3 MANAGEMENT OF ABNORMAL CYTOLOGY REPORT AND REFERRAL PATHWAY 11

4 PRINCIPLES/INDICATIONS FOR COLPOSCOPY..... 15

5 COLPOSCOPY SETTING 17

6 INTERPRETATION OF COLPOSCOPIC FINDINGS..... 21

7 DIAGNOSIS AND TREATMENT FACILITIES 43

8 COUNSELLING AND ADVICE AFTER TREATMENT 53

9 FOLLOW UP 55

10 CASE BASED DISCUSSIONS 57

11 MONITORING AND EVALUATION 59

12 STANDARD OPERATING PROCEDURE – COLPOSCOPY 63

ANNEX I - INFECTION PREVENTION 71

ANNEX II - PREPARATION OF SOLUTIONS 77

**ANNEX III - MANAGEMENT OF SCREEN POSITIVE WOMEN BASED ON COLPOSCOPY AND
HISTOPATHOLOGY DIAGNOSIS..... 83**

REFERENCES 84

FOREWORD

Cervical cancer is a highly preventable cancer because there are screening tests to detect pre-cancerous lesions and a vaccine to prevent Human Papilloma Virus (HPV) infections. When cervical cancer is detected early, it is highly treatable and associated with good survival and better quality of life. It is the most common female cancer in many low- and middle-income countries and the 3rd most common female cancer in Sri Lanka. World Health Organization (WHO) has initiated a global strategy towards eliminating cervical cancer as a public health problem. In order to achieve this global strategy, every country should reach the following global targets by 2030.

- 90% coverage of HPV vaccination of girls (by 15 years of age)
- 70% coverage of screening with high performance test by the ages 35 and 45 years and treatment of 90% of pre-cancerous lesions.
- Management of 90% of invasive cancer cases

Out of these three targets, HPV vaccination and pap smear screening are being carried out successfully throughout the country with the guidance, supervision, monitoring and evaluation of the Epidemiology unit and the Family Health Bureau respectively.

In order to treat 90% of pre – cancerous lesions, colposcopy services need to be strengthened at secondary/tertiary care hospitals where pap positive patients are being referred to. The National Cancer Control Programme been the national focal point of cancer prevention and control in the country, has taken steps to establish new colposcopy centers and streamline available colposcopy services to utilize colposcopy services maximally. Further steps were taken to develop training module, guideline and standard operating procedures (SOP) which will be used for capacity building of relevant clinicians including postgraduate trainees, etc.

This training module, guideline and standard operating procedure had been developed by the National Cancer Control Programme with the expertise of relevant clinicians who have undergone colposcopy training (World Health Organization mediated) in Chandigarh, India.

The objective of preparing this book which consist of training module, guideline and standard operating procedure is to enhance the knowledge and skills of relevant clinicians to perform diagnostic and therapeutic procedures using the Colposcopes to achieve the global target of treating 90% of pre-cancerous cervical lesions.

EXECUTIVE SUMMARY

Cervical cancer is the most common gynaecological malignancy worldwide. In Sri Lanka, it is the third commonest female cancer and nearly 1000 new invasive cervical cancer cases reported per annum. The deaths related to cervical cancer carries a significant burden to the family as women dying due to this cancer are relatively young.

Even though, there is a definite pre-cancerous stage which can readily be detected by screening and treated effectively to prevent the lesion becoming an invasive cancer, most of the cervical cancer patients in Sri Lanka are detected beyond the stage 2.

The National Control Program for cervical cancer has three arms namely, vaccination of young girls to prevent them getting HPV infection, screening with pap smears to detect pre-cancerous lesions and providing colposcopy treatments. The approximate pap smear coverage at national level is around 60% of the target female population. However, due to the inadequacy of secondary/tertiary referral points, there may be dropouts from screen positive women.

Therefore, colposcopy services need to be strengthened at secondary/tertiary care hospitals to streamline cervical cancer prevention/control strategy. Colposcopy training is a part of gynaecological postgraduate training and further augment at gynae-oncology training. However, availability of training module, guideline and standard operating procedure will facilitate the gynaecologists to further improve colposcopy services.

Colposcopy is an essentially a sophisticated clinical skill and specialist judgement which is highly subjective. Accurate diagnosis depends on the experience of the clinician. In order to improve the quality of the services, capacity building of relevant officers plays an integral part.

The path we adopted is for training, accreditation and revalidation of human resource followed by an audit. This training module is developed to accredit doctors who already had gynaecology post-graduate training to practice colposcopy in Sri Lanka. Training module is developed in accordance with WHO guidance and training.

LIST OF ABBREVIATIONS

AIS	Adenocarcinoma in situ
ASCUS	Atypical Squamous Cells of Undetermined Significance
ASR	Age Standardized Rate
AW	Acetowhite
CA	Cancer
CIN	Cervical Intraepithelial Neoplasia
CKC	Cold Knife Conization
CTZ	Congenital Transformation Zone
FDA	Food and Drug Administration
HBV	Hepatitis B Virus
HG	High Grade
HIV	Human Immunodeficiency Virus
HLD	High Level Disinfection
HPV DNA	Human Papilloma Virus Deoxyribo Nucleic Acid
HPV	Human Papilloma Virus
HSIL	High Grade Squamous Intraepithelial Lesion
IFCPC	International Federation of Cervical Pathology and Colposcopy
IV	Intravenous
LEEP	Loop Electrosurgical Excision Procedure
LG	Low Grade
LLETZ	Large Loop Excision of the Transformation Zone

LRMP	Last Regular Menstrual Period
LSIL	Low Grade Squamous Intraepithelial Lesion
MOOH	Medical Officers of Health
NCCP	National Cancer Control Programme
NILM	Negative for Intraepithelial Lesion or Malignancy
PCR	Polymerase Chain Reaction
PID	Pelvic Inflammatory Disease
SCJ	Squamocolumnar Junction
TZ	Transformation Zone
WHO	World Health Organization
WWC	Well Women Clinics

CHAPTER 1

INTRODUCTION

1.1 Cervical cancer burden

1.1.1 Global situation

Cervical cancer is the fourth commonest female cancer globally with an estimated 570,000 new cases in 2018 which is equal to 6.6% of all female cancers in the world. During the same year, there were an estimated 311,365 deaths from cervical cancer accounting for 7.5% of the total number of cancer deaths in women. Approximately 90% of these deaths are occurring in low to middle income countries.

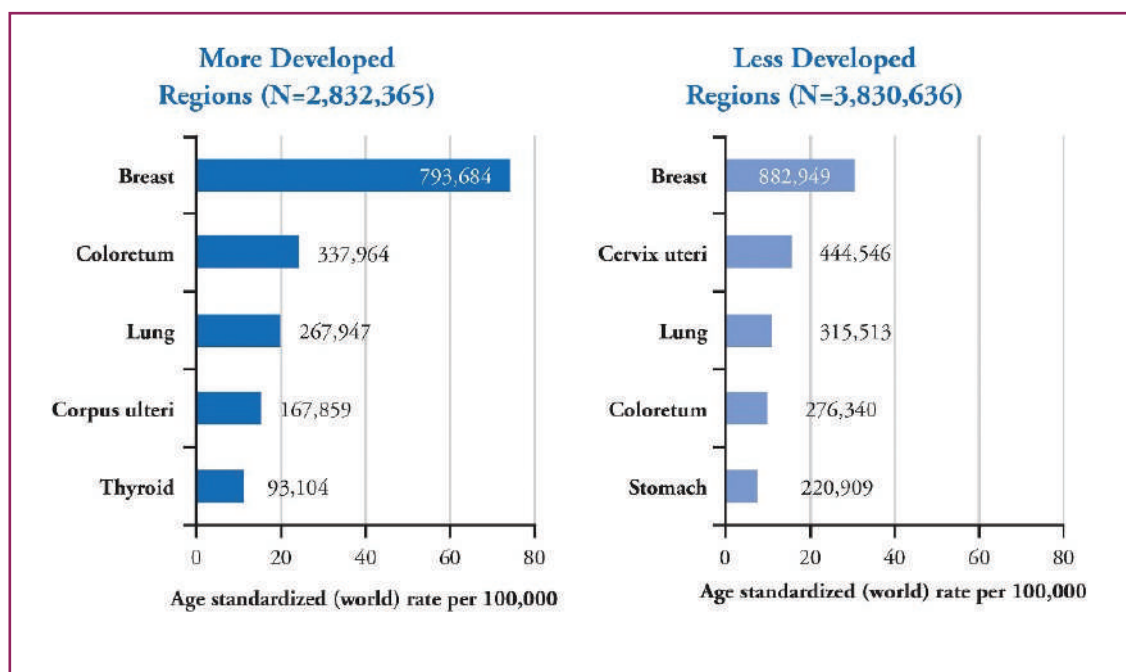


Figure 1.1 Most common female cancers in more developed and less developed countries

Source: Ferlay et al., GLOBOCAN 2012:(<http://globocan.iarc.fr>.)

1.1.2 Cervical cancer burden in Sri Lanka

Cervical cancer is the third commonest female cancer in Sri Lanka. According to the latest published national cancer incidence data 2012, there were 905 incident cases of cervical cancer with the crude rate of 8.6 per 100,000 female population and Age Standardized Rate (ASR) of 7.2 per 100,000 female population.

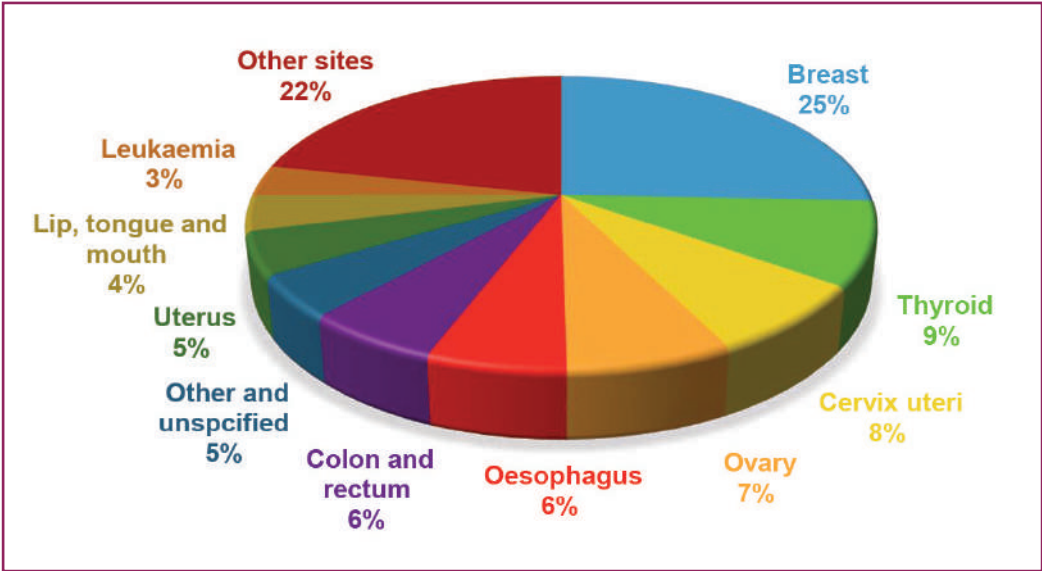
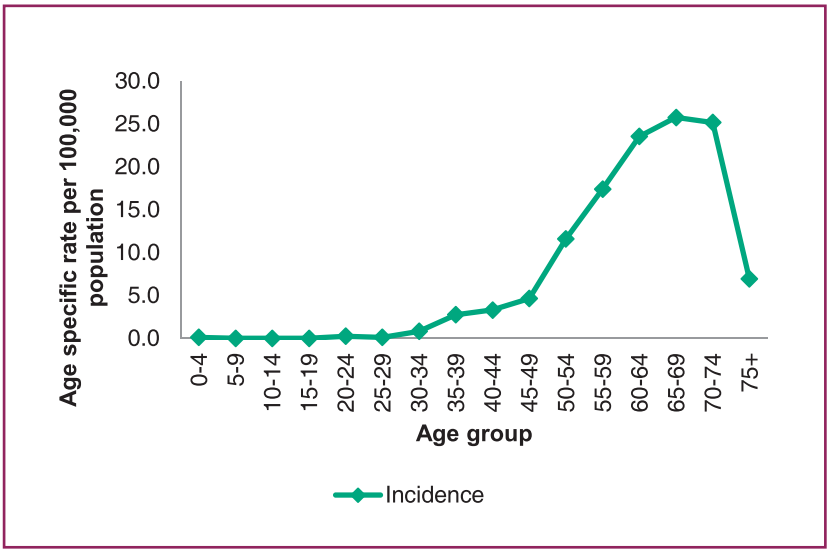


Figure 1.2 Proportion of leading cancers, female – 2012
Source: National Cancer Incidence and Mortality Data Sri Lanka – 2012

1.1.3 Common age groups affected



96% of cervical cancer cases are females of above 40 years of age (year 2012) with very few cases in the age groups below 40 years

Figure 1.3 Age specific rates - Cervix uteri in 2012
Source: National Cancer Incidence and Mortality Data Sri Lanka – 2012

1.1.4 Cervical cancer trends over the years

Compared to many other cancers, cervical cancer incidence is remaining static over the years. In 2006, the ASR was 9.6 per 100,000 population and since 2008 the ASR remains between 8.6 to 8.2 per 100,000.

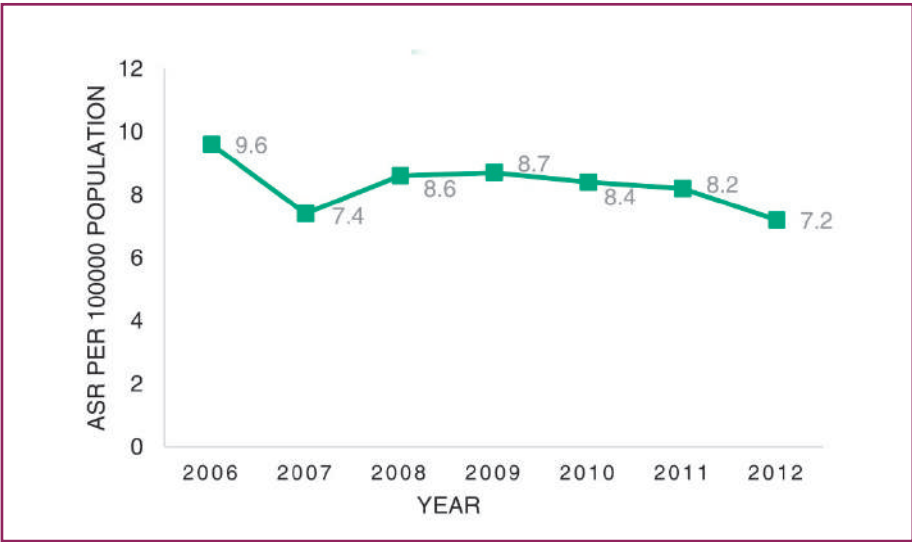


Figure 1.4 ASR, 2006-2012- Cervix uteri
Source: National Cancer Incidence and Mortality Data Sri Lanka – 2012

1.1.5 Stage at diagnosis

According to the cancer incidence data 2011, out of all diagnosed invasive cervical cancer patients, 56% of cases were having staging information. It shows that more than 50% (53.1%) of patients were diagnosed at the stage III or stage IV when the prognosis is poor.

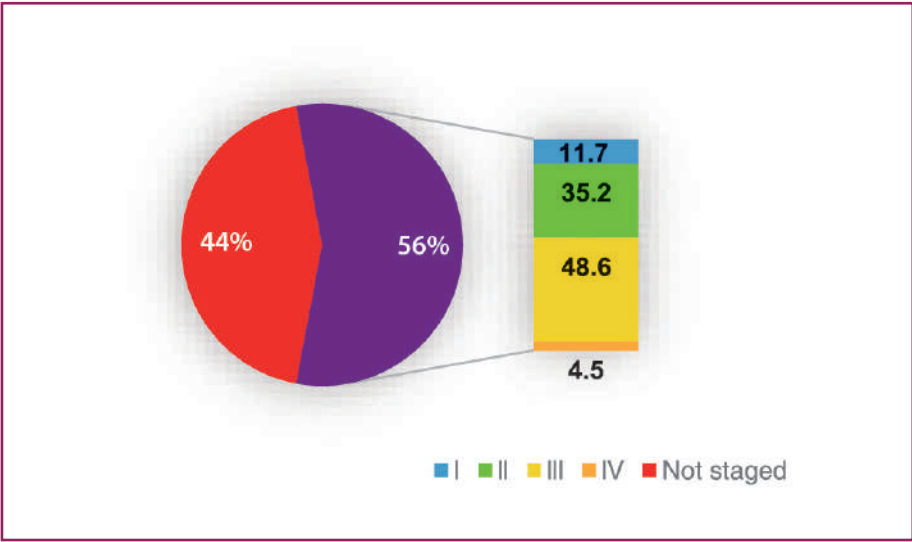
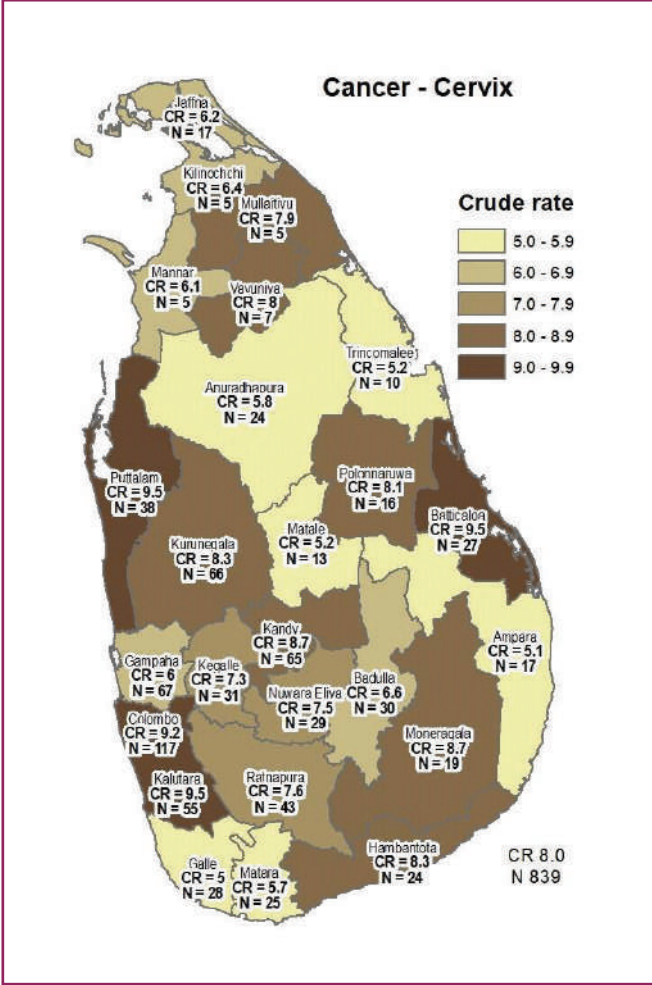


Figure 1.5 Stage at diagnosis – Cervical cancer
Source: Cancer Incidence Data Sri Lanka - 2011

1.1.6 Distribution of cases by district



2011 cancer incidence data reveals that highest crude incidence rate of cervical cancer which is above 9 per 100,000 female population was seen in Puttalam, Colombo, Kalutara and Batticaloa.

Figure 1.6 Geographical distribution of cervical cancer cases
Source: Cancer Incidence Data Sri Lanka - 2011

1.2 Current cervical cancer screening programme in Sri Lanka

National cervical cancer screening programme conducted through the well - organized Well Women Clinics (WWC) and supplemented by mobile clinics conducted in the community and work places. The screening test carried out in these clinics is conventional pap test. In 2018, HPV DNA testing is carried out in Kalutara district as a pilot project in order to assess the feasibility and cost effectiveness of the test to supplement pap smear testing. Depending on the pilot study results, it will be possible to introduce HPV DNA testing to national cervical cancer screening programme, FDA approved PCR technique was used for HPV DNA detection. Women belong to 35 and 45 years cohort was introduced and following protocol was used.

Screening for cervical cancer – Algorithm for HPV DNA Test

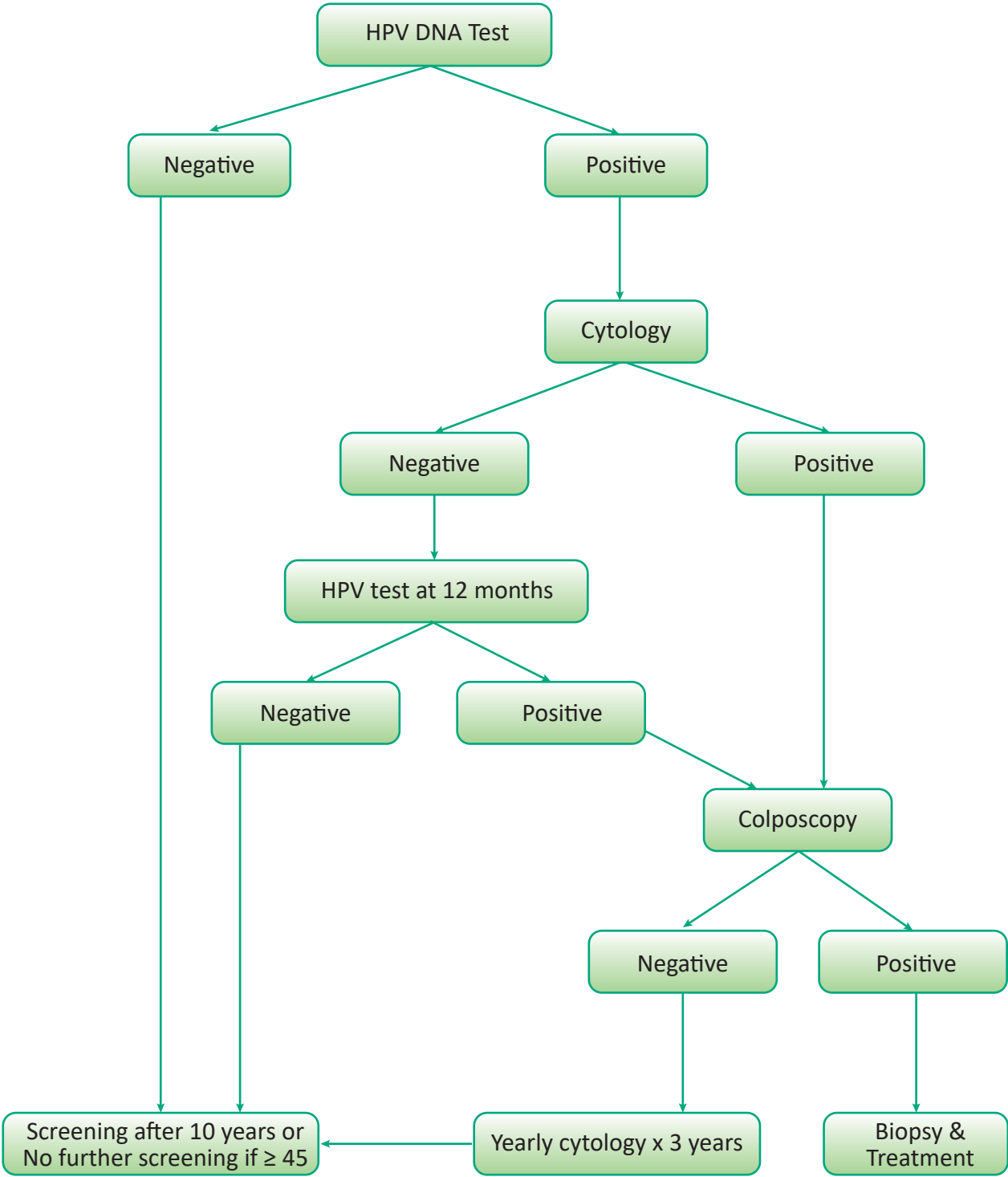


Figure 1.7 Screening for cervical cancer – Algorithm for HPV DNA Test
Source: National Strategic Plan 2019-2023, Well Woman Programme, Family Health Bureau

1.2.1 Well Women Clinic

The Well Women Clinic programme was established in 1996, at the time when the reproductive health concept was introduced into primary health care services with the objective of improving the health of women in the country. By the end of 2016, approximately 850 WWCs were functioning island wide. According to the revised guideline for implementation of WWC services, following decisions were taken.

- All Medical Officers of Health, heads of all health institutions and MOOH of Municipal Councils should have functioning WWCs in their respective institutions/hospitals.
- Any woman between 35 to 60 years of age (including those in the peri-menopausal age or in menopause) should be encouraged to attend WWC services.
- There should be at least one WWC per 15,000 population and clinics should be held at least once a month.

1.2.2 Screening guideline in Sri Lanka

The primary target age for cervical cancer screening is the cohort of women who are at 35 years of age. From 1st of July 2016 the 45 years age cohort was also included as a target age group for cervical cancer screening.

While actively campaigning for the cohort of women aged 35 and 45 years for cervical cancer screening, those who voluntarily request should also be screened depending on the service availability.

CHAPTER 2

PATHOPHYSIOLOGY OF CERVICAL PRE-CANCEROUS LESION AND CANCER

2.1 Human Papilloma Virus and cervical cancer

Human Papilloma Virus (HPV) is the necessary cause for cervical pre-cancer and invasive cervical cancer. It has been shown that nearly 100% of cervical cancers and pre-cancers are caused by persistent HPV infection. It is a common sexually transmitted infection that does not cause any signs/symptoms and many women infected with HPV infection do not develop cervical cancer. Many infected women can clear the infection due to their natural immunity. Very few women with persistent HPV infection (oncogenic HPV types) will develop cervical pre-cancer lesions and cervical cancer. Cervical cancer is a rare outcome of oncogenic HPV infection. It may take minimum of 10 years to develop a cervical cancer once infected with HPV.

At least 200 genotypes of HPV have been described including 40 viral types transmitted sexually and affect the genital area. Of these, 15 genotypes have oncogenic properties, including sub types HPV 16, 18, 31, 33, 35, 39, 45, 51, 52, 56, 58, 59, 68, 73 and 82. Only 1:10 to 1:30 HPV infections are associated with abnormal cervical cytology. Woman with a negative cytology and a positive HPV DNA test result has a 15% chance of developing an abnormal cervical cytology within 5 years.

A persistent HPV infection is necessary for the development of all invasive cancers, studies have found that HPV DNA is positive in 99.7% of cervical cancers. In fact, more than 90% of new HPV infections are cleared within two years of infection, with clearance typically occurring within the first 6 months after infection. Cervical cancer is extremely rare with negative HPV testing.

2.2 Spread of HPV infection

- HPV infection spreads through sexual contact. However, penetrative sex is not necessary for the virus to be transmitted between sex partners because virus can be transmitted through genitalia-to-genitalia, skin-to-skin or skin-to-genitalia.
- HPV infection may also be transmitted by nonsexual routes that includes vertical transmission from a woman to a newborn infant at the time of birth (Respiratory Papillomatosis) and also by fomites.

2.3 Risk factors for the development of cervical cancer

- Age above 40 years and ever been sexually active
- Sexual debut at very young age
- Multiple sex partners or partners having multiple sex partners
- Too many children, especially at young age
- Low socio-economic status
- Smoking
- Not being screened for cervical cancer
- Infection with Chlamydia
- HIV infection and poor immunity

Women are at highest risk of acquiring HPV infection when they initiate their sexual life. Use of condoms and male circumcision give partial protection against infection and transmission of HPV.

2.4 Development of cervical cancer

When a woman contracted Human Papilloma virus, it enters the basal layer of squamous epithelium via small breaches in cervical epithelium closer to squamocolumnar junction and infect the basal layer. Virus synchronized with epithelial cell division and divide within the basal cells. These cells gradually move towards the surface and shed off.

If the infection is persistent, viral DNA incorporates into the host DNA and produces harmful onco-proteins (E6/E7), thus disrupts normal regulatory mechanisms of cell division and leads to a cervical cancer.

2.5 Cervical Intraepithelial Neoplasia

Cervical Intraepithelial Neoplasia (CIN) is a pre - malignant condition resulting from unregulated division of squamous cells of the cervical epithelium due to persistent HPV infection. According to the severity of the abnormality and the extent of involvement of squamous epithelial thickness, these lesions are graded as;

CIN 1 – Mild dysplasia

CIN 2 – Moderate dysplasia

CIN 3 – Severe dysplasia and Carcinoma in situ

Premalignant lesions arising from columnar epithelium are known as Adenocarcinoma in situ.

2.5.1 Cervical Intraepithelial Neoplasia 1

In this stage, the abnormal dysplastic cells are limited to the lower one third of the epithelium.

There is 57% chance of regression of the lesion and the progression to invasive cancer is rare.

This is also known as Low Grade Squamous Intraepithelial Lesion (LSIL).

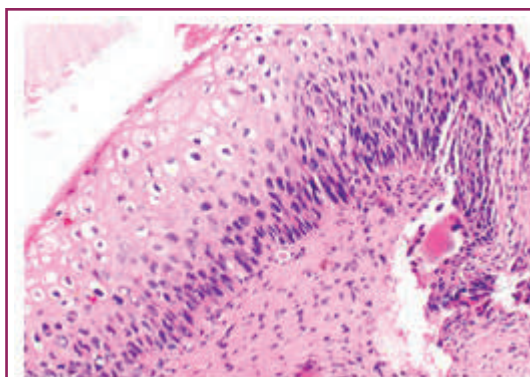


Figure 2.1 CIN I

Source: *Training of health staff in colposcopy, LEEP and CKC - Trainees' handbook*, World Health Organization, 2017

2.5.2 Cervical Intraepithelial Neoplasia 2

In this stage, the abnormal dysplastic cells can be seen up to the middle third of the epithelium and the chance of regression is 43%.

Also known as High Grade Squamous Intraepithelial Lesion (HSIL).

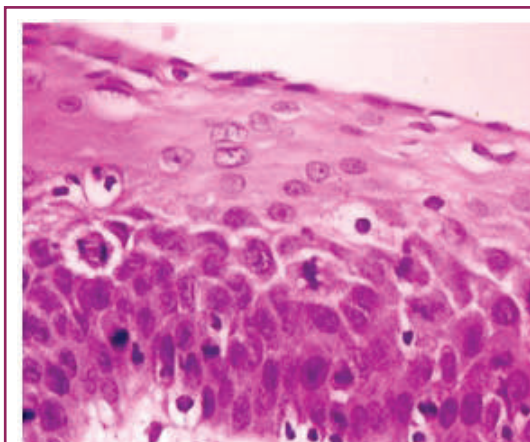


Figure 2.2 CIN II

Source: *Training of health staff in colposcopy, LEEP and CKC - Trainees' handbook*, World Health Organization, 2017

2.5.3 Cervical Intraepithelial Neoplasia 3

The abnormal dysplastic cells extend up to the upper third of the epithelium in this stage. Thus, there is a high potential for progression and only 32% possibility of regression.

Also known as High Grade Squamous Intraepithelial Lesion.

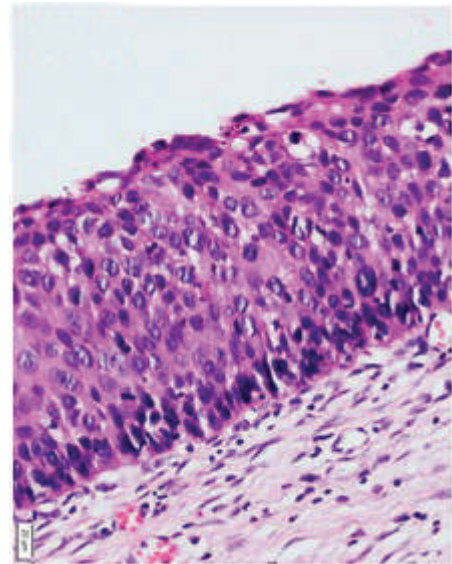


Figure 2.3 CIN III

Source: Training of health staff in colposcopy, LEEP and CKC - Trainees' handbook, World Health Organization, 2017

2.6 Steps in cervical carcinogenesis

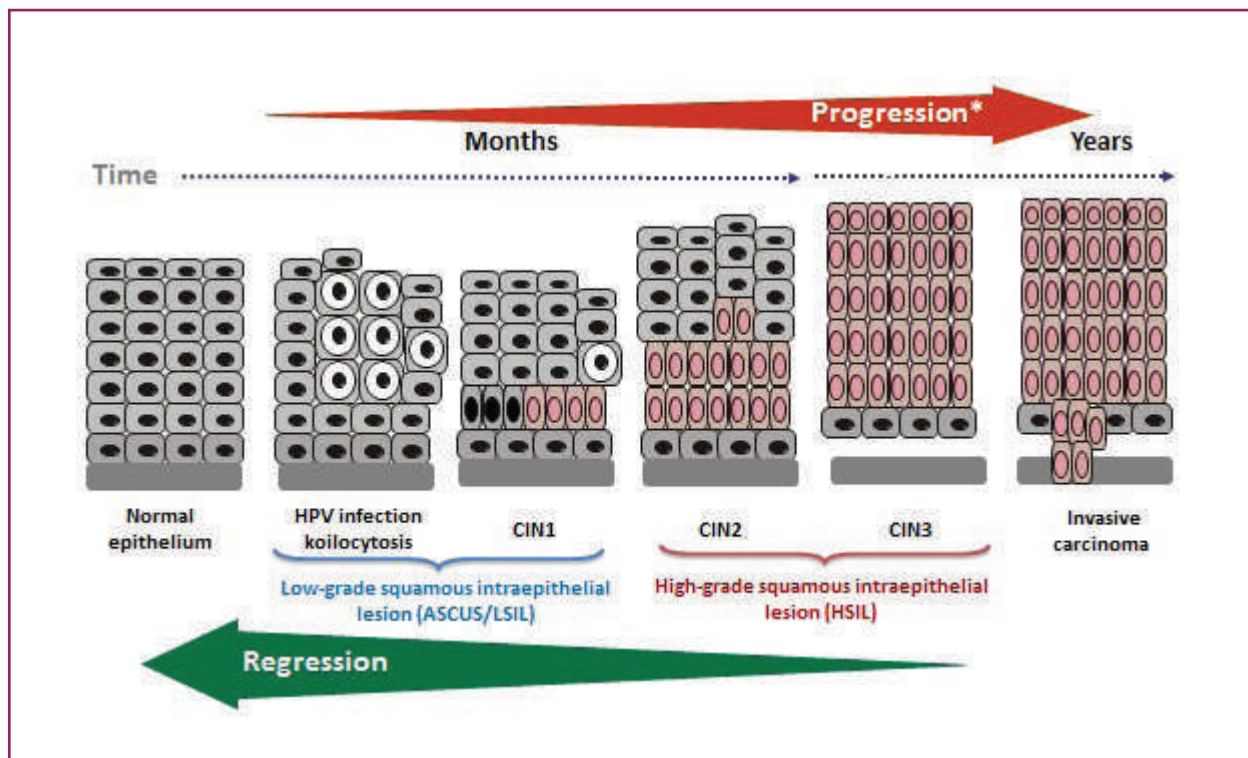


Figure 2.4 Steps in cervical carcinogenesis

Source: Burd EM. Clin Microbiol Rev 2003; 16:1–17; Solomon D, et al. JAMA 2002; 287:2114–2119

CHAPTER 3

MANAGEMENT OF ABNORMAL CYTOLOGY REPORT AND REFERRAL PATHWAY

3.1 Introduction

Cervical cancer screening in the world has resulted in marked reduction of cervical cancer incidence and cancer related mortality. Out of the different screening techniques used for cervical cancer all over the world, conventional pap smear is the main cervical cancer screening tool in Sri Lanka. The value of an accurate screening can be lost when there is no appropriate protocol for follow up and referral for further management. Therefore, this chapter is to introduce a guidance on how to deal with abnormal cervical cytology.

Bethesda system is currently used to define different abnormal cervical cytology smears. Following categories are included in modified classification adapted for Sri Lanka.

1. Negative for Intraepithelial Lesion or Malignancy (NILM)
2. Low grade Squamous Intraepithelial Lesion (LSIL)
3. High grade Squamous Intraepithelial Lesion (HSIL)
4. Atypical Squamous Cells of Undetermined Significance (ASCUS)
 - Atypical Squamous Cells of Undetermined Significance – Low grade (ASCUS - Low grade)
 - Atypical Squamous Cells of Undetermined Significance – High grade (ASCUS - High grade)
5. Glandular cell atypia
6. Benign endometrial cells in a woman > 40 years
7. Squamous or Glandular Malignancy

3.2 Guidance for management of abnormal smears

Following table describes recommended management strategies of different abnormal smear results.

Cytological classification (Modified Bethesda System adapted to Sri Lanka)	Histological classification (used for diagnosis)	Recommendation
Normal	Normal	Routine re-screening (5 yearly). If inflammatory – treat and follow up
ASCUS – Low grade	Atypia	Medical officer at primary health care level to follow up and repeat smear in 6 months
ASCUS – High grade		Refer for colposcopy If colposcopy biopsy is positive, treat as for HSIL
LSIL	CIN 1 (including flat condylomata)	If HPV DNA is not available, repeat smear in 6 months. If second smear also LSIL or above → refer to a gynaecologist for colposcopy. If HPV DNA is available, triage → If HPV DNA positive + LSIL → refer for colposcopy.
HSIL	CIN 2 / CIN 3	Refer for colposcopy
Glandular cell atypia		Refer for colposcopy
Invasive carcinoma	Invasive carcinoma (Squamous or Glandular malignancy)	Urgent referral to a Tertiary Cancer Center (For gynaecologist opinion)

Table 3.1 Guidance for management of abnormal smears
 Source: Family Health Bureau

3.3 Referral pathway for colposcopy

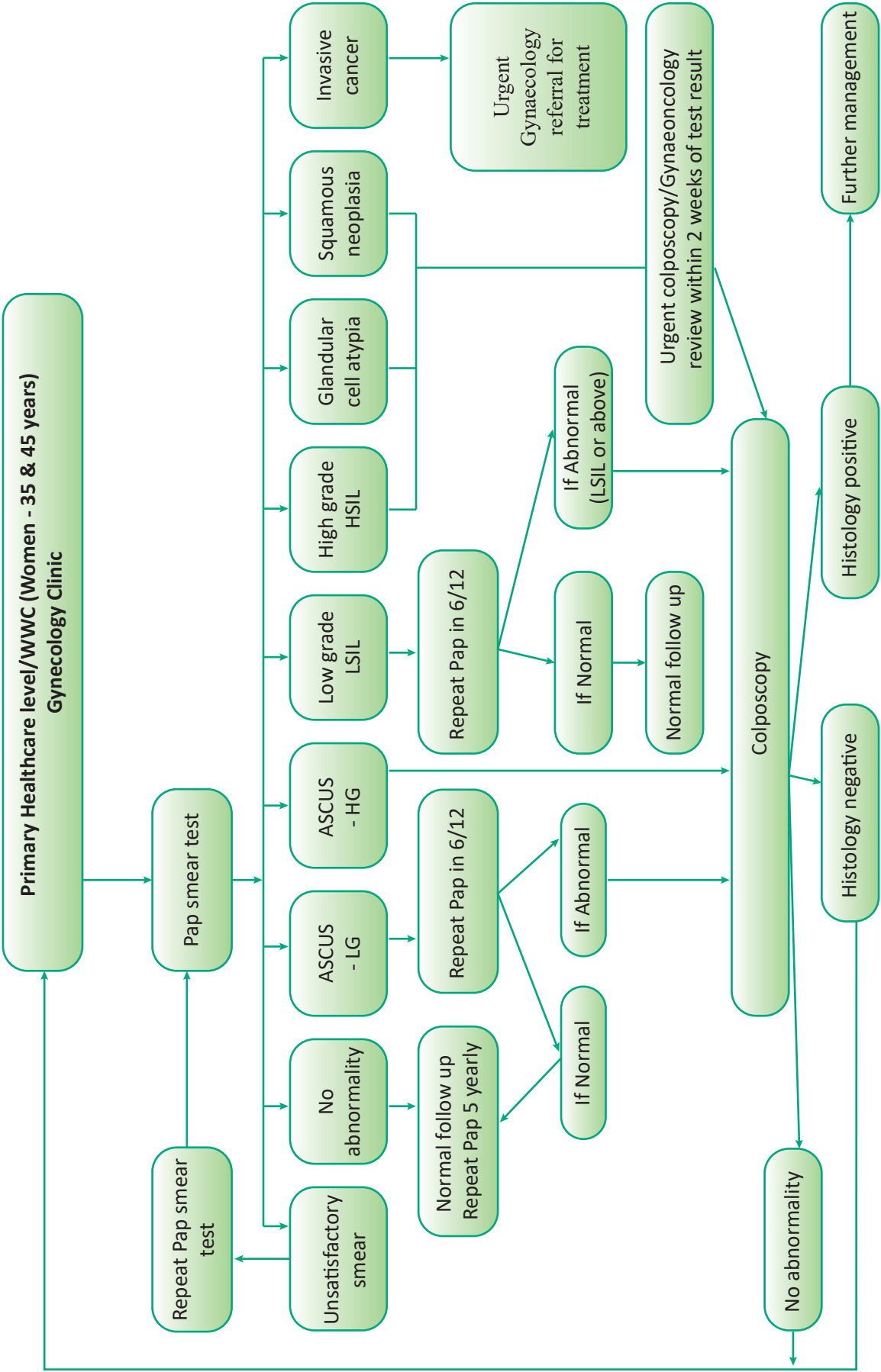


Figure 3.1 Referral pathway for colposcopy

CHAPTER 4

PRINCIPLES/INDICATIONS FOR COLPOSCOPY

Colposcopy is a diagnostic procedure to detect abnormalities of the cervix through magnification ranging from 4x to 30x.

The aim is to differentiate between normal cervix, non-neoplastic conditions, low grade neoplasia, high grade neoplasia and invasive lesions based on the changes observed.

The lining of the cervix consists of two cell types. Columnar epithelium lines the endocervical canal and is composed of a single monolayer of mucus-producing cells that form epithelial fronds visible through the Colposcope.

When columnar epithelium extends onto the ectocervix, it appears as a red zone surrounding the os and is called ectropion or ectopy. Squamous epithelium, on the other hand, is smooth, pale pink in colour and consists of stratified layers up to 15-20 cells thickness.

It is divided into basal, parabasal, intermediate and superficial layers. The squamous epithelium of the vagina and cervix is nonkeratinized. The junction between columnar and squamous cell layers is referred to as the squamocolumnar junction, which is visible on the ectocervix in younger women.

Transformation zone (TZ) is the area between the original squamocolumnar junction and the new squamocolumnar junction which comprised of mature squamous epithelium distally and columnar epithelium proximally and is the site of active squamous metaplasia. At any time, the TZ may have columnar epithelium, squamous metaplasia and squamous epithelium.

The TZ moves cephalad as a woman aged. In younger women, the TZ is usually found circumferentially at the external cervical os, whereas in older women it may have receded within the endocervical canal. Thus, in postmenopausal women, the presence of ectropion is uncommon. When a woman becomes pregnant, the cervix markedly increases in size and weight. Concomitant with the size increase, there is usually an eversion of the endocervical (columnar) epithelium.

Over 90% of cervical neoplasia occurs in the cervical TZ. The reasons for the susceptibility of the TZ for neoplastic transformation are not known. However, it may be related to increased cell proliferation and tissue remodeling secondary to squamous metaplasia in the TZ and propensity of the TZ to be infected with human papilloma virus and the high concentration of inflammatory and immune cells in the TZ. Given the fact that the TZ is the “hotspot” for neoplastic transformation, the goal of colposcopy is to identify the TZ, assess whether it can be seen entirely, identify any abnormal areas and obtain appropriate samples for histological assessment. The overarching goal is to identify the highest grade of disease present in order to determine the treatments needed and the type of treatment.

In a patient with abnormal cytology, colposcopy is performed to identify abnormal areas in the TZ that correspond to the cytologic findings. Most neoplastic changes are not visible to the naked eye but are visible under binocular magnification after application of 3–5% acetic acid solution. When acetic acid is applied to the areas of CIN or invasive cancer, it undergoes maximal coagulation due to their high content of cellular and nuclear protein. The higher the grade of CIN, the higher is the concentration of abnormal cellular and nuclear protein and more - denser is the aceto-whitening.


4.1 Relative contraindications for colposcopy

- Non-cooperative patient
- Presence of menstruation
- Presence of active cervicitis

CHAPTER 5

COLPOSCOPY SETTING

Setting up of your Colposcope correctly is the key to provide successful colposcopy services and interpretation of the findings. This chapter provides stepwise guide to set up your Colposcope correctly, which will help to give correct instructions to your staff.



1. Magnification changer	8. LED illumination unit
2. Horizontal drive	9. Green filter
3. Connecting tube	10. Clamp nut for tilt adjustment
4. Vertical drive	11. Lamp cable
5. Thread for mounting plate	12. Eye pieces
6. Front lenses	13. Prism bodies
7. Lamp optics	

Figure 5.1 Parts of the Colposcope

5.1 Parts of the Colposcope

1. Holders to adjust - Helps to move the Colposcope in all four directions.
2. Binocular eye piece -Makes the focus according to the refraction of each eye. Always take the binocular vision as it gives the 3D pictures.
3. Magnification knob - Gives the various levels of magnification.
4. Fine tuning knob - Adjusts the finer view to get accurate details.
5. Fine focus.
6. Green filter - Enhances blood vessels to see vascular abnormalities.

The check list before starting the procedure

- Bed or inclined chair with leg holders (Make sure that adequate exposure is obtained)
- Cleaning solution - Cleaning has to be done with a clear solution
- Insulated Cusco's bivalve speculum with smoke evacuator line.
- Compatible electro surgical system
- Loops, Roller ball tips
- Freshly prepared 5% acetic acid and Lugol's Iodine
- Cotton swabs (Peanut swabs) for application.
- Endocervical speculum
- Monsel's solution
- Instrument trolley
- Vaginal packs, pads

Clinic setting - The room setting has to be an ambient environment to ease the patients. Colposcopist needs to communicate with the patient throughout the procedure.

- A. Instrumentation and technique (refer SOP page no: 66 - 67)
- B. Required consumables (refer SOP page no: 64 - 65)
- C. Preparation of acetic acid and Lugol's Iodine (refer Annex II page no: 77 - 79)
- D. Disinfection of instrument (refer Annex I page no: 73 - 75)

5.2 Troubleshooting in colposcopy

Common problems encountered in colposcopy

- In multiparous women with lax vaginal wall, it will fill up the vagina between the blades of the speculum obstructing the view
Solutions:
 - use large Cusco's speculum
 - cover the ends of blades using a non-lubricated condom or finger of glove (tips cut)
 - use lateral vaginal wall retractor
- Severe vaginitis
 - Should be treated before colposcopy
- Visualization of SCJ difficult due to mucus and misinterpreted as acetowhite area
 - Remove the mucus using a cotton swab which will be easier after application of acetic acid
- Visualization of outer limits of the lesion may be difficult due to the presence of large TZ in hypertrophied cervix
 - Use large speculum
 - Check for abnormalities quadrant by quadrant
- Very vascular cervix, large ectropion or excessive mucus in pregnancy
 - Mucus should be removed gently to avoid bleeding
 - Taking biopsy should be limited to rule out cancer
- Incomplete visualization of SCJ
 - Endocervical speculum could be used
- Atrophic vaginitis/vulvitis/cervicitis
 - Speculum should be lubricated
- Incomplete visualization of TZ in post-menopausal women
 - Woman should be advised to use oestrogen vaginal cream or oral tablets for 2 -3 weeks and come to the clinic in 1 month for repeat colposcopy

- Bleeding in post-menopausal women due to thinned out cervical epithelium
 - Gentle insertion of speculum
 - Lubrication of speculum
 - Wiping off blood gently with saline or acetic acid
- No correlation between histopathological diagnosis and colposcopic findings
 - Take biopsy from acetowhite area closer to SCJ
 - Take several biopsies if the lesion is large
 - Freshly prepared acetic acid of appropriate dilution should be used and wait for 1 minute minimum before taking biopsies
- Biopsy is not adequate for histopathological assessment
 - Use sharp cutting biopsy forceps
 - Take biopsy with small loop if necessary

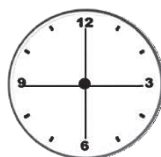CHAPTER 6

INTERPRETATION OF COLPOSCOPIC FINDINGS

Interpretation of colposcopic findings depends on many factors. The history of the patient is very important. Following sequence is fairly helpful.

1. History of the patient – Age, previous pap test, LRMP, pregnancy test
For an example – irregular per vaginal bleeding could be due to a cervical polyp
2. Colour of the cervix under yellow light and green light
3. Look for active metaplastic process
 - a. Crypt opening
 - b. Nabothian cysts
 - c. Islands of columnar epithelium
4. Identify transformation zone (Type 1, Type 2, Type 3)
5. Pattern of the blood vessels
6. Appearance after application of 5% acetic acid and acetowhite area
7. Location of the lesion: inside TZ / outside TZ / both inside and outside TZ:

Clock position (Please mark below)



Number of quadrants involved: 1/ 2/ 3/ 4

Size of lesion: <25% / 25–50% / 50–75% / >75%

8. Appearance after application of Lugol's Iodine

6.1 Colposcopic features of mature squamous epithelium

Mature squamous epithelium appears bluish or pink in colour and may have fine capillaries or normal branching blood vessels. Features suggestive of active metaplastic process like crypt openings, nabothian cysts, metaplastic epithelium or islands of columnar epithelium are usually not seen. After application of acetic acid there is no acetowhite changes. At the periphery of the ectocervix, mature squamous epithelium can be seen which is the native epithelium of the cervix. However, with advancing age, the metaplastic epithelium over the TZ also becomes fully mature. With the application of Lugol's Iodine, mature squamous epithelium will be stained evenly.

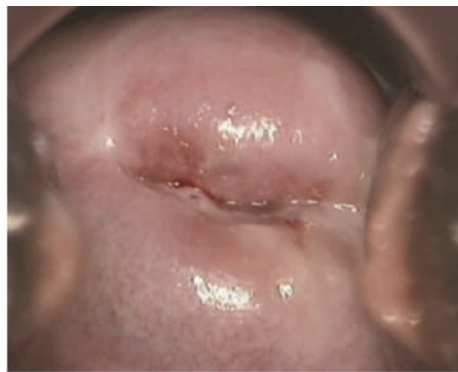

Figure 6.1 Mature squamous epithelium
Source: Training of health staff in colposcopy, LEEP and CKC - Trainees' handbook, World Health Organization, 2017

6.2 Colposcopic features of atrophic squamous epithelium

Atrophic squamous epithelium appears thin and pale pink in colour. The cervix becomes flush with vagina and difficult to see SCJ properly as it recedes inside the endocervical canal. Blood vessels which are normal can be seen prominently through the thin epithelium. Subepithelial bleeding (petechial haemorrhagic spots) probably be seen during manipulation. There are no acetowhite areas after application of acetic acid. With application of Lugol's Iodine, the epithelium is either not stained or partially stained.

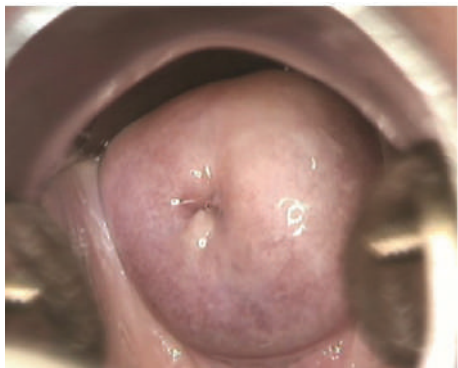

Figure 6.2 Atrophic squamous epithelium
Source: Training of health staff in colposcopy, LEEP and CKC - Trainees' handbook, World Health Organization, 2017

6.3 Appearance of normal cervix

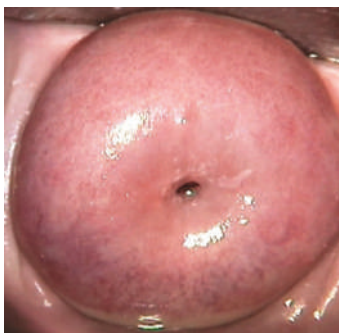

Figure 6.3 Nulliparous cervix: pin point external os
Source: Training of health staff in colposcopy, LEEP and CKC - Trainees' handbook, World Health Organization, 2017

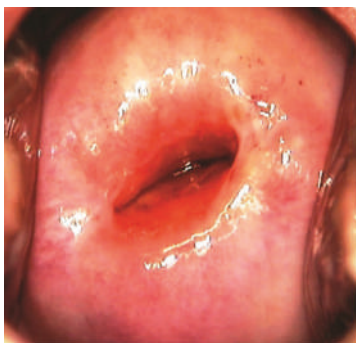


Figure 6.4 Multiparous cervix: slit like external os
Source: Training of health staff in colposcopy, LEEP and CKC - Trainees' handbook, World Health Organization, 2017

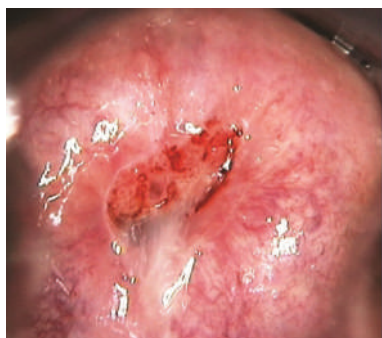

Figure 6.5 Mature cervix - Normal mucoid discharge from external os

Source: Training of health staff in colposcopy, LEEP and CKC - Trainees' handbook, World Health Organization, 2017

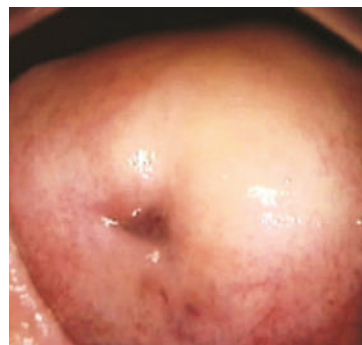


Figure 6.6 Atrophic cervix – Pale ectocervix

Source: Training of health staff in colposcopy, LEEP and CKC - Trainees' handbook, World Health Organization, 2017

6.4 Colposcopic features of Ectropion

Presence of columnar epithelium on the ectocervix up to varying distance from the external os is referred as Ectropion or Ectopy. The SCJ can be easily identified on the ectocervix especially after application of acetic acid. Columnar epithelium is visible as a red patch with normal branching blood vessels prior to the application of acetic acid. The columnar epithelium becomes more prominent after application of acetic acid. Presence of finger-like projections of villi of columnar epithelium give a velvet-like granular appearance and often the fissures are visible. Due to the blanching of the blood vessels, columnar epithelium may become white immediately after application of acetic acid. However, this acetowhite change is transient and becomes the original red colour within few seconds.

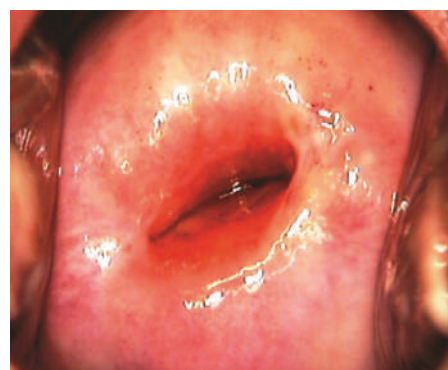


Figure 6.7 Large Ectropion - Columnar epithelium has a red velvet like appearance

Source: Training of health staff in colposcopy, LEEP and CKC - Trainees' handbook, World Health Organization, 2017

6.5 Cervical changes seen in pregnancy

Cervix enlarges, becomes soft and congested during pregnancy and is covered by copious mucus. Averted and hypertrophied columnar epithelium can be seen. During second and third trimester, the stroma of the cervix may undergo focal decidual changes which appears as a raised plaque or as a pseudo polyp. During pregnancy the blood vessels are prominent.

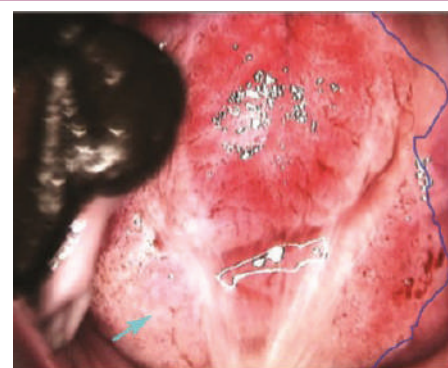


Figure 6.8 Cervical changes seen in pregnancy

Source: Training of health staff in colposcopy, LEEP and CKC - Trainees' handbook, World Health Organization, 2017

6.6 Cervico – vaginal infections

The commonest pathological condition in the cervix and vagina is inflammation due to various microorganisms. Most commonly found infective agents are *Candida albicans* (Fungus), *Trichomonas vaginalis* (protozoa), *Chlamydia trachomatis* (bacteria), *Gardnerella vaginalis* (bacteria), *Escherichia coli* (bacteria) and *Streptococci* (bacteria). Rarely, *Herpes simplex* virus too can infect the cervix. It is worth of noting the character of discharge in the vagina and around the cervix during colposcopy as it may help to detect the type of infection.

6.6.1 Trichomonas infection

Frothy, greenish and foul-smelling discharge can be seen in Trichomonas infection. The cervix is often tender on movement. Trichomonas infection may produce a “strawberry” appearance of the cervix with alternating areas of red epithelium and pale dots on the surface of the cervix. After applying Lugol’s Iodine, typical leopard skin appearance can be seen due to multiple Iodine negative patches.

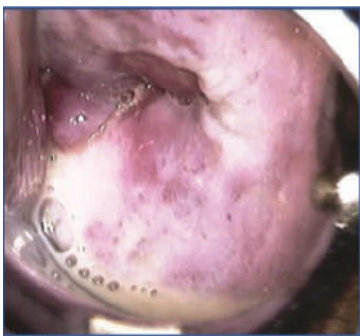


Figure 6.9 Thin frothy discharge of Trichomoniasis

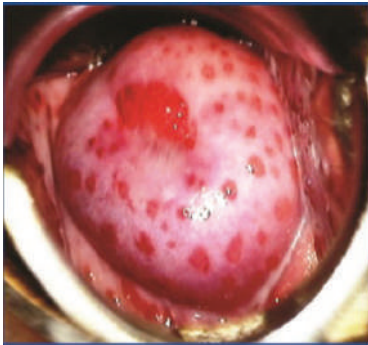


Figure 6.10 Strawberry appearance of cervix in Trichomoniasis

Source: Training of health staff in colposcopy, LEEP and CKC - Trainees’ handbook, World Health Organization, 2017

6.6.2 Candida Infection

In candida infection, there is curdy white and often sticky discharge.

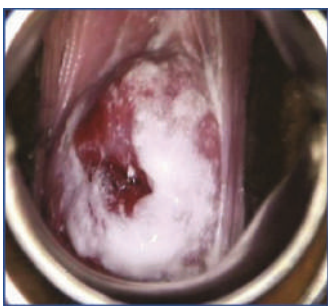


Figure 6.11 Curdy white thick discharge of Candidiasis

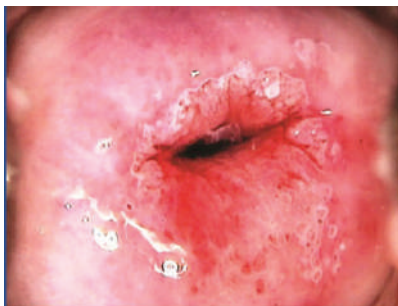

Figure 6.12 Thick cheesy white discharge on the cervix

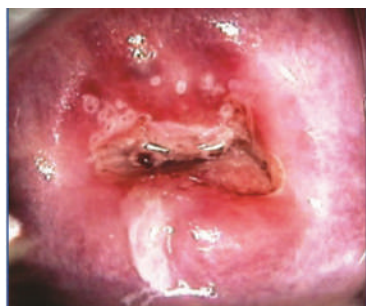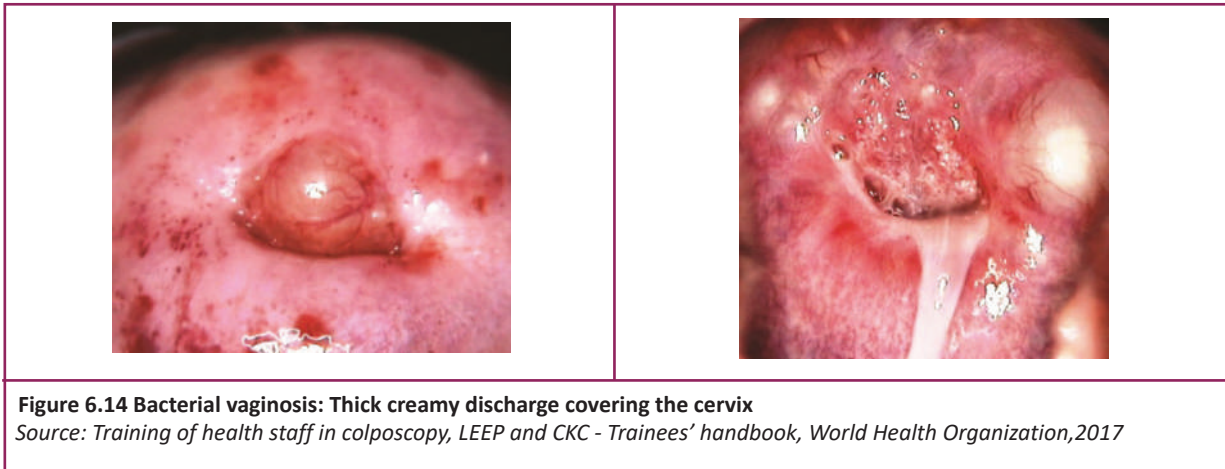


Figure 6.13 Thick curdy white discharge covering the cervix

Source: Training of health staff in colposcopy, LEEP and CKC - Trainees’ handbook, World Health Organization, 2017

6.6.3 Bacterial infection

Fishy smelling greenish or yellowish discharge can be seen



6.6.4 Chlamydia or Gonococcal infection

An inflamed red and swollen cervix with pus coming out from the external os, also called Cervicitis, commonly seen in this type of infections. Infected areas might bleed on contact.

6.6.5 Herpes infection

May give rise to vesicles and/or small multiple ulcers on the cervix, vagina and vulva. Inflammation is a miscellaneous finding according to the IFCPC 2011 classification.

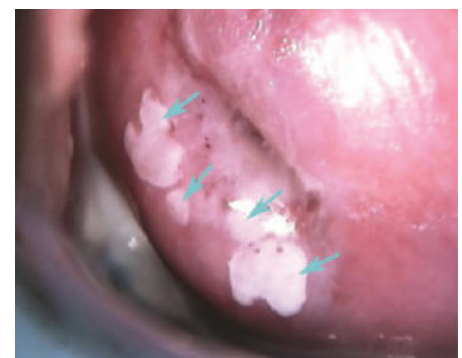6.6.6 Features of condyloma or genital warts

Condyloma (wart) in the genital area is caused by low risk HPV types. This can affect the external genitalia, vagina and cervix and most of the time it is multiple. Lesions in the cervix usually appear as distinct lumpy and irregular lesions. They may look bright white irregular, pitted or spiky. There may be finger like projections on the surface with a central capillary in each of the projections. Majority of condyloma can be seen after application of acetic acid.

- **Subclinical papilloma virus infection**

Multiple satellite lesions with irregular margins, most of the time away from the TZ can be seen as acetowhite areas.

Condyloma is a miscellaneous finding according to the IFCPC 2011 classification.



6.7 Leukoplakia

In leukoplakia, white patch/s can be seen even before the application of acetic acid. Due to the deposition of keratin in the epithelial cells, it looks like a plaque on the cervix having shiny surface. The cause of leukoplakia can be due to condylomas or idiopathic. A high -grade lesion or a cancer might be hidden due to leukoplakia. Therefore, it is necessary to take biopsies from all leukoplakia patches on the TZ of the cervix. Leukoplakia is a “non-specific abnormal colposcopic finding” according to the IFCPC 2011 classification.

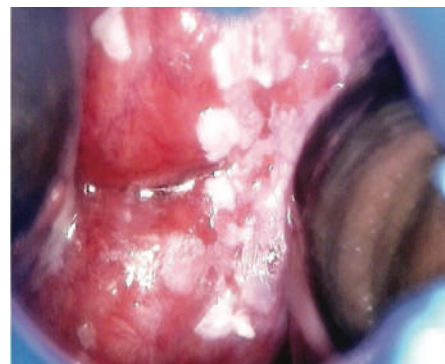


Figure 6.16 Leukoplakia
Source: Training of health staff in colposcopy, LEEP and CKC - Trainees’ handbook, World Health Organization, 2017

6.8 Cervical polyp

Overgrowth of the endocervical columnar epithelium result in cervical polyp. It may be visible as single or multiple red colour mass protruding from the external os. Cervical polyp is usually mobile and it can be moved here and there to visualize the squamocolumnar junction. Even though polyps do not stain with Lugol’s Iodine, it can be seen as acetowhite area due to metaplastic changes. Polyp is a miscellaneous finding according to the IFCPC 2011 classification.

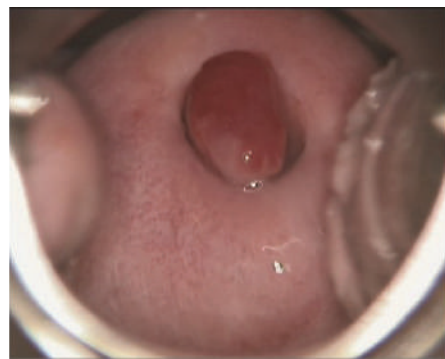

Figure 6.17 Cervical polyp
Source: Training of health staff in colposcopy, LEEP and CKC - Trainees’ handbook, World Health Organization, 2017

6.9 Endometriosis of the cervix

Endometriosis of cervix looks like small blue or red surface nodules through the Colposcope. Usually these nodules are very small (few millimeters in diameter), located in the cervical canal or on the portio. Endometriosis is a miscellaneous finding according to the IFCPC 2011 classification.

6.10 Cervical erosion

Denudation of cervical epithelium is called erosion which can be detected due to the presence of following features;

- Absence of surface epithelium
- Exposed stroma with thin spider like blood vessels
- Peeled off denuded epithelium

The peeled off epithelium seen hanging loosely is known as “rag sign”. In erosion there is no finger like projections of the villi of columnar epithelium which is present in ectropion. Erosion is present commonly in post-menopausal and/or grossly infected cervixes. However, patient with high grade cervical neoplasia or cancer can be present with an erosion. Therefore, if erosion found closer to TZ, it should be carefully evaluated and if necessary, need to take multiple punch biopsies from eroded area and surrounding areas. Erosion is a nonspecific finding according to the IFCPC 2011 classification.

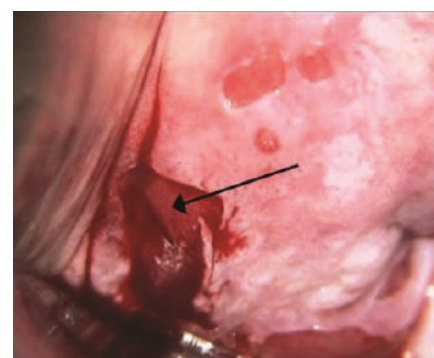


Figure 6.18 Cervical Erosion*

6.11 Metaplastic squamous epithelium

The villi of columnar epithelium become flattened and merge with each other at the initiation of metaplastic process. Metaplasia can be seen as multiple glassy islands of newly formed squamous epithelium or else as pale, translucent in – growths of metaplastic epithelium from the original squamous epithelium. These in-growths appear as tongue like projections. These islands and in-growths can coalesce into sheets of immature metaplasia, often with a thin acetowhite line at the advancing border.

Immature metaplasia looks pale pink in colour and has fine mosaic pattern which can turn acetowhite. The patent crypt openings visible as black dots surrounded by thin acetowhite rim are characteristic of metaplastic epithelium and are useful to delineate the extent of the TZ. Nabothian cysts can be seen as white or yellowish blisters or pimples on the TZ with flattened branching blood vessels on the surface.

* Source: Training of health staff in colposcopy, LEEP and CKC - Trainees' handbook, World Health Organization, 2017

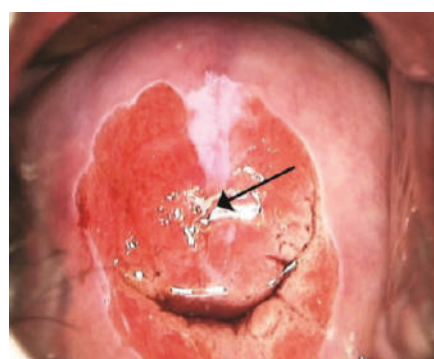


Figure 6.19 Immature squamous metaplasia*

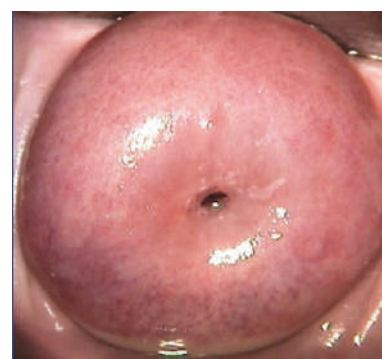

Figure 6.20 Columnar epithelium villi become flattened and fuse together giving a thin glassy appearance*

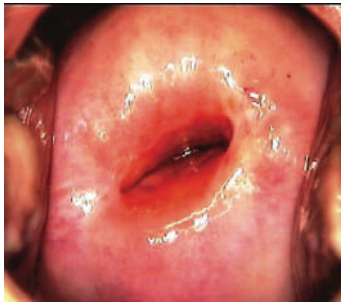


Figure 6.21 Metaplasia progresses from the SCJ towards the external os

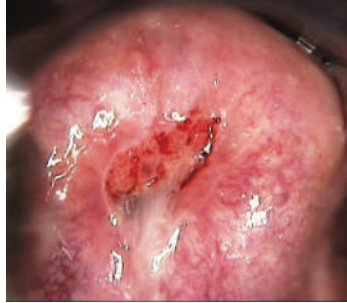


Figure 6.22 Metaplastic epithelium appears faintly acetowhite with tongue-like projections towards external os. Note the islands of columnar epithelium

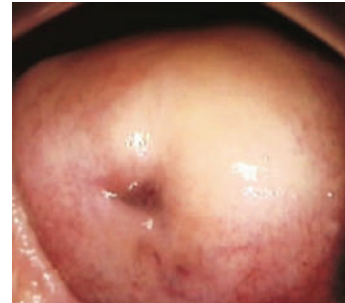
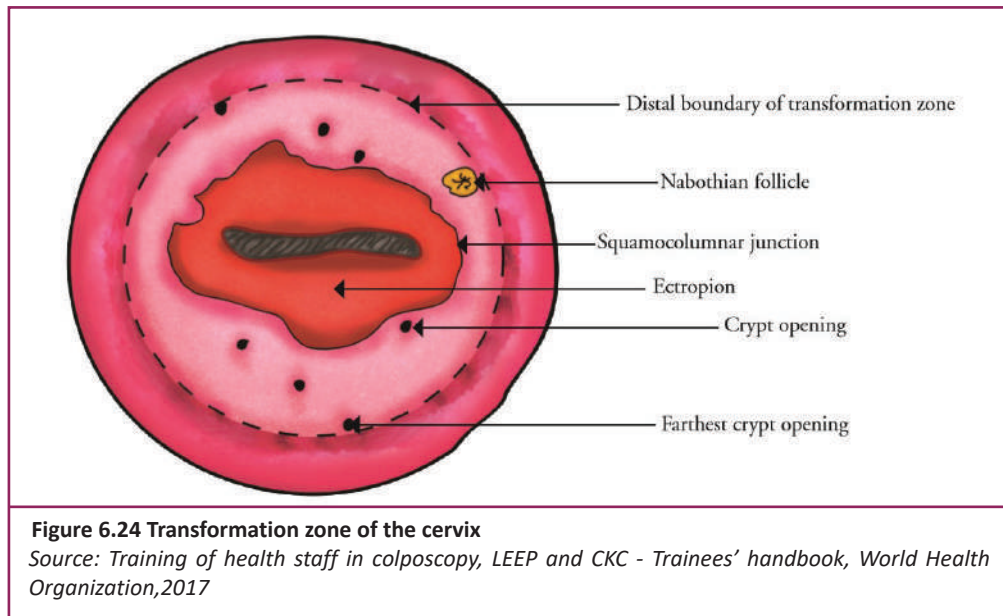


Figure 6.23 Metaplastic epithelium is faintly acetowhite

Source: Training of health staff in colposcopy, LEEP and CKC - Trainees' handbook, World Health Organization, 2017

6.12 Transformation zone

The transformation zone is the area where columnar epithelium is replaced by or in the process of being replaced by metaplastic squamous epithelium. Squamous metaplasia usually initiates at the original SCJ at the distal limit of the ectropion and gradually moves inwards (centripetally) towards the external os. As a result, SCJ also moves towards external os. Area between the original SCJ and the new SCJ (SCJ visible during colposcopy) which is formed because of metaplasia is transformation zone.



As almost all cervical pre-cancers and squamous cell carcinomas occur in the TZ, it is essential to examine the TZ. Prior to interpret colposcopy results it is mandatory to observe whole TZ. Extent of the TZ should be correctly identified in order to make decisions regarding treatment of cervical pre-cancers.

6.12.1 Congenital transformation zone

Congenital transformation zone appears as a large oblong shaped thin acetowhite area on the cervix extending from anterior to posterior vaginal fornices. This appearance is due to abnormal maturation of the squamous epithelium. The area is not stained with Iodine and has fine mosaic patterns. 4 -5% of women undergoing colposcopy have CTZ which does not have any malignant potential. CTZ is a miscellaneous finding according to the IFCPC 2011 classification and therefore no treatment is needed.

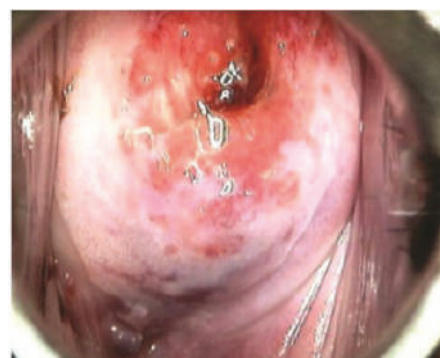

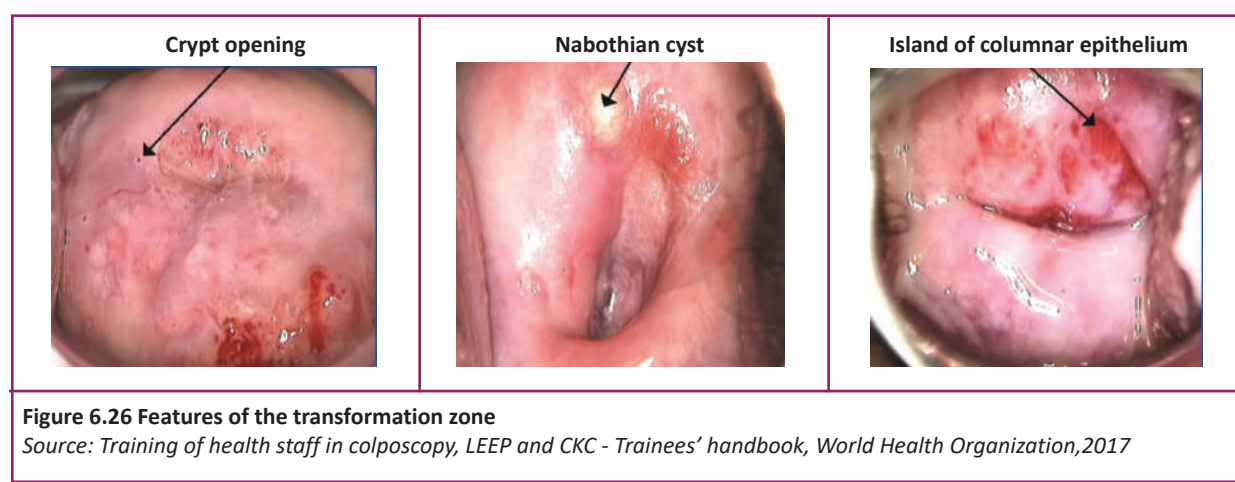
Figure 6.25 Congenital transformation zone
Source: *Training of health staff in colposcopy, LEEP and CKC - Trainees' handbook*, World Health Organization, 2017

6.12.2 Features of a normal transformation zone

Following are the features of normal transformation zone.

- Newly formed thin transparent squamous epithelium with immature metaplasia characterized by tongue like projections.
- Openings of the crypts which appears as small black spots on colposcopy
- Crypt openings can be blocked by metaplastic epithelium which result in development of nabothian cysts. These appears as white or yellow cysts (pimples) on the cervix colposcopically.
- 'Skip areas' can be seen due to the presence of islands of columnar epithelium which have not covered with columnar epithelium yet.
- Identification of the distal limit of the TZ will be made easy by recognizing the position of the crypt opening or the nabothian cyst farthest from the SCJ (the proximal limit of the TZ is always the SCJ).

6.12.2.1 Features of the transformation zone



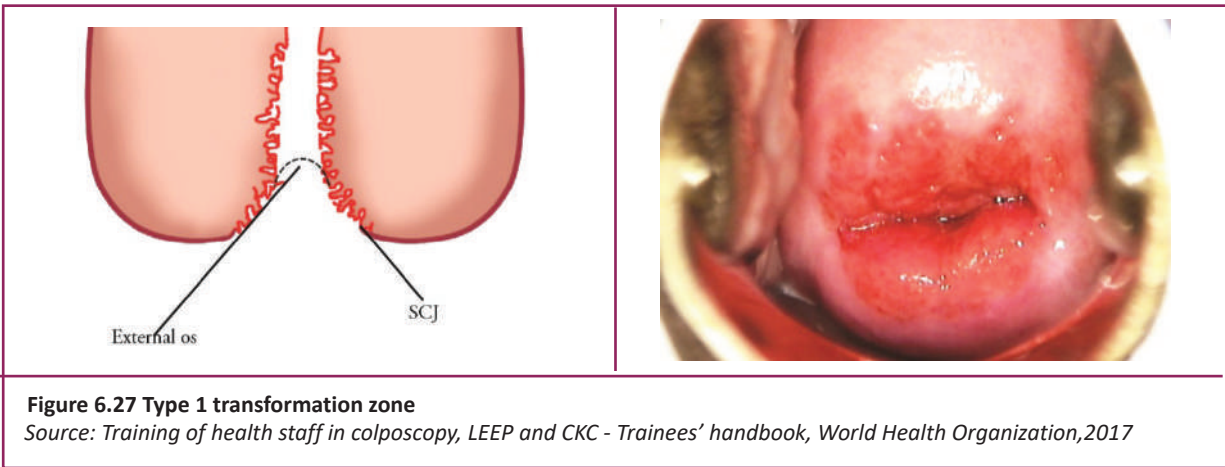
6.12.3 Types of transformation zone

The TZ can be categorized in to following types depending on the location of the SCJ.

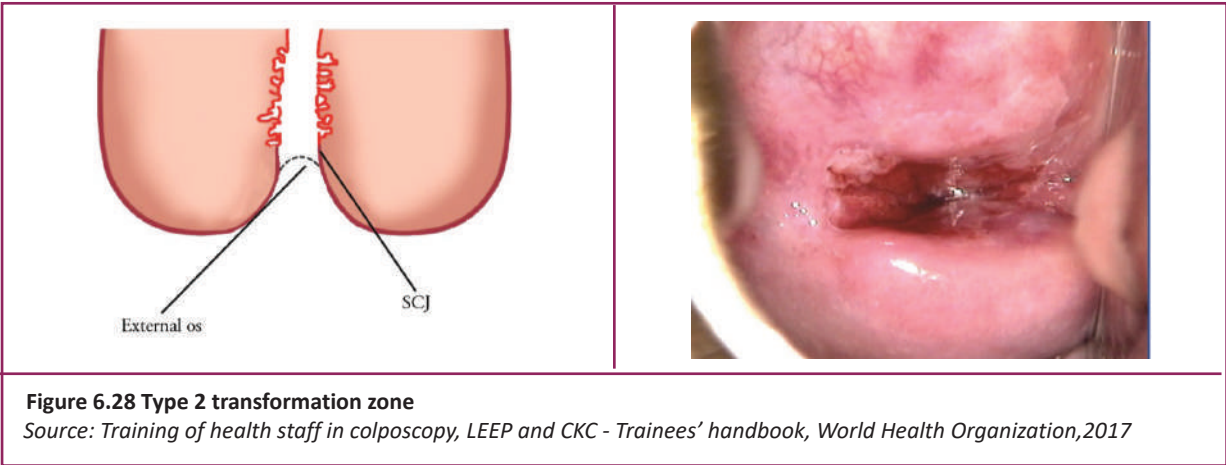
- Type 1: The SCJ is fully visualized either at the external os or on the ectocervix.
- Type 2: The SCJ is fully visualized but it is located in the endocervical canal fully or partially.
- Type 3: The SCJ is within the endocervical canal and it is only partially visualized or not visualized at all.

6.12.4 Classification of the transformation zone

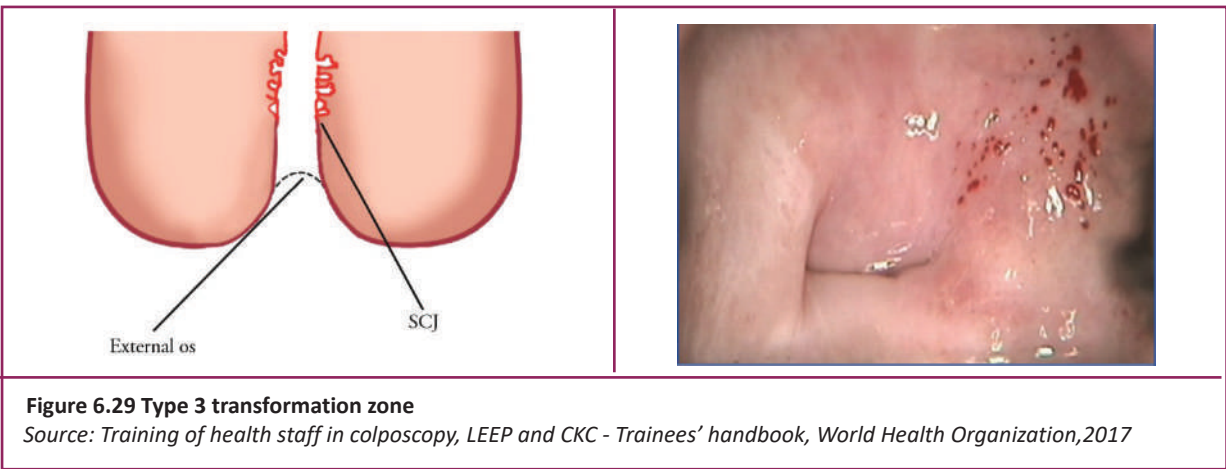
- Type 1 transformation Zone



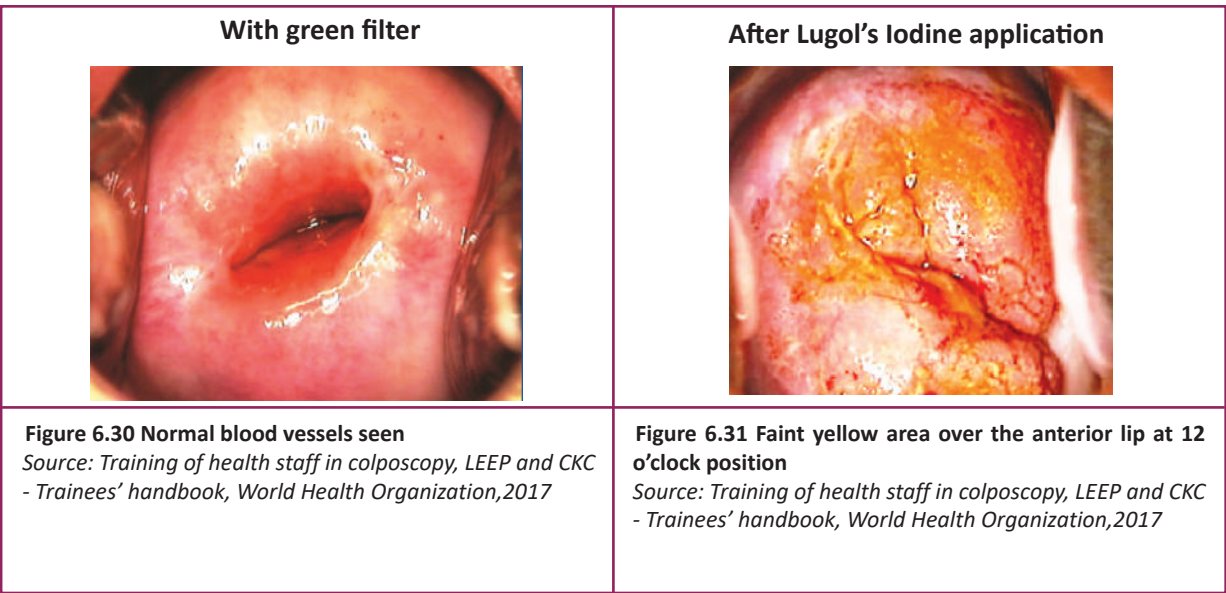
- **Type 2 transformation Zone**




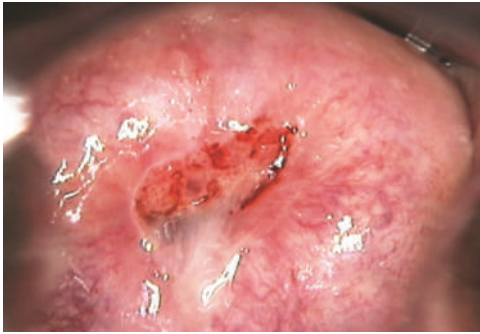
- **Type 3 transformation Zone**



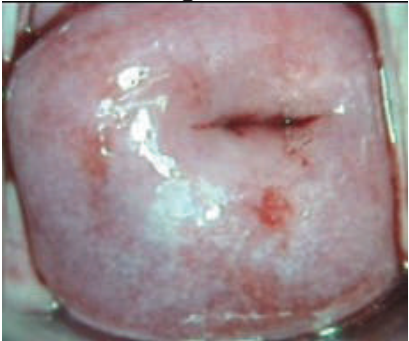

6.12.4.1 Type 1 transformation zone (with green filter & Lugol's Iodine)



6.12.4.2 Type 2 transformation zone (with normal saline & acetic acid)

<p>After normal saline application</p> 	<p>After acetic acid application</p> 
<p>Figure 6.32 Ectocervix appears normal, SCJ partially visible</p>	<p>Figure 6.33 SCJ is partly inside the endocervical canal, but fully visible. Thin acetowhite area is noted in three quadrants with feathery and geographical margins</p>
<p>Source: Training of health staff in colposcopy, LEEP and CKC - Trainees' handbook, World Health Organization, 2017</p>	

6.12.4.3 Type 3 transformation zone (with green filter & acetic acid)

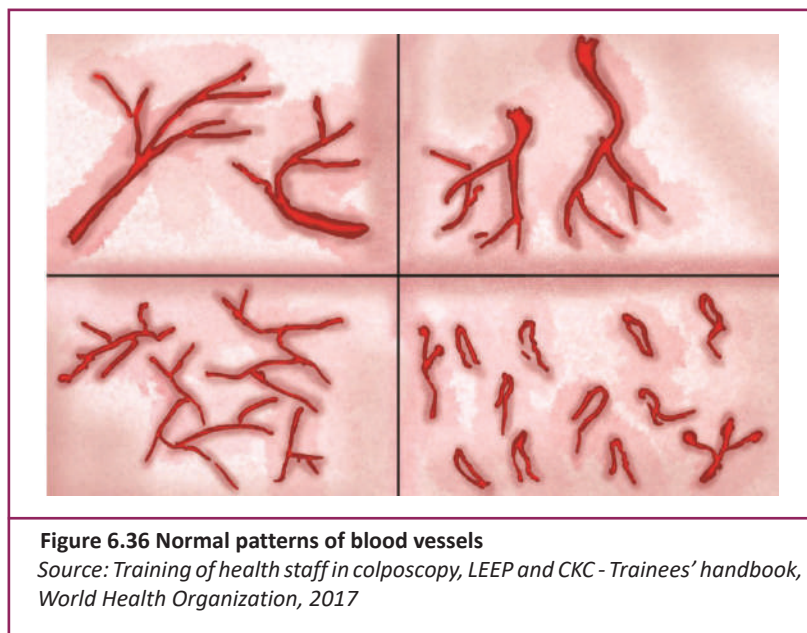
<p>With a green filter</p> 	<p>After acetic acid application</p> 
<p>Figure 6.34 No abnormal vessels seen</p>	<p>Figure 6.35 SCJ inside the canal and not fully visible. Thin acetowhite area noted at 6-7 o'clock position with geographical margins</p>
<p>Source: Training of health staff in colposcopy, LEEP and CKC - Trainees' handbook, World Health Organization, 2017</p>	

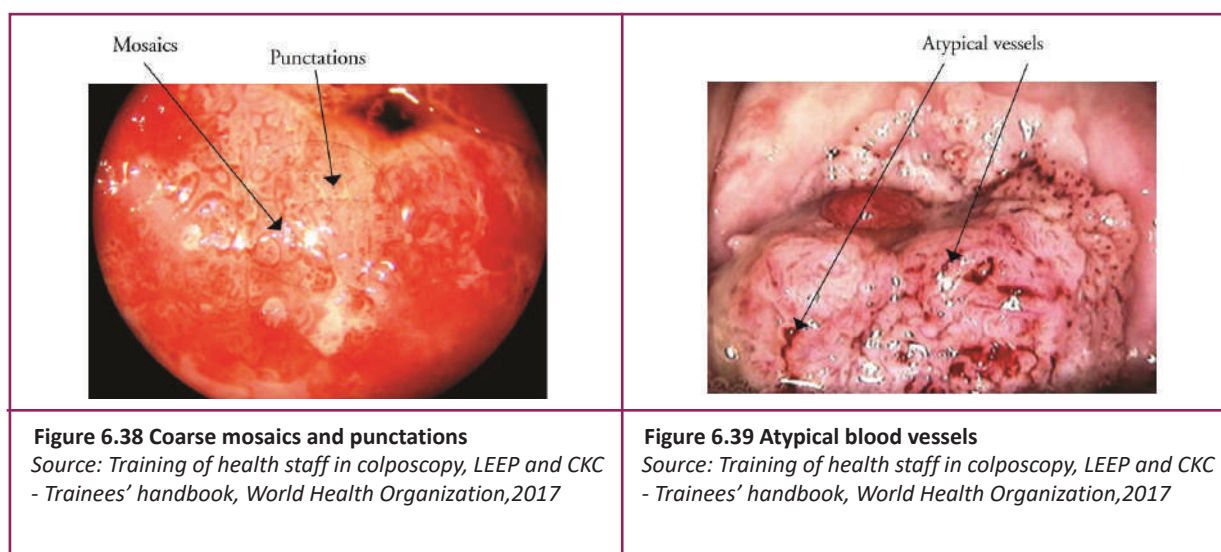
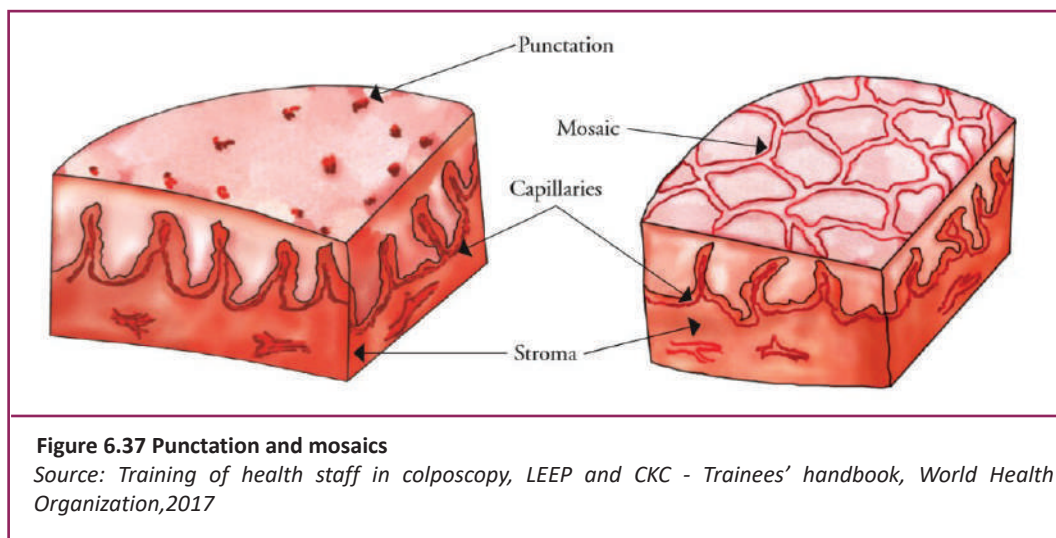
6.13 Normal and abnormal blood vessel patterns

- The vascular pattern of the cervix can be visualized better with the use of green / blue filter and after application of normal saline.
- A branching pattern of blood vessels can be seen in normal cervix which composed of a central stem and smaller branches starting from the stem.
- Fine hairpin like blood vessels or network of capillaries might be visible at the periphery of the cervix.
- A cobble-stone appearance on colposcopy which is called 'mosaic' is due to the network of interconnecting blood vessels running parallel to the surface of the epithelium. Mosaics can be fine or coarse.

- The capillaries are fine and uniform in caliber and disposition in fine mosaic.
- In coarse mosaic, the blood vessels are prominent, irregular in caliber and are absent at some places.
- Fine mosaic is commonly seen in immature metaplasia, HPV lesions or low grade lesions, while in high grade lesions or cancer, coarse mosaic is a characteristic feature.
- An area of red dots denoting stromal papillae and blood vessel loops reaching the surface epithelium to produce a stippling appearance which is known as punctation. These punctations usually be fine or coarse in nature.
- In fine punctation, the capillaries are fine and evenly distributed.
- In coarse punctations, there are prominent red dots which are raised from the surface and irregularly spread and may bleed at touch.
- While fine punctations are commonly seen in an inflamed cervix, immature metaplasia and low grade lesion, coarse punctations can be seen in high grade lesions or cancer.
- Blood vessels which are atypical have bizarre shapes, indefinite branching patterns and unequal thickness. These atypical blood vessels are usually raised from the surface, shiny and easily bleed at touch.

- **Normal blood vessel pattern**

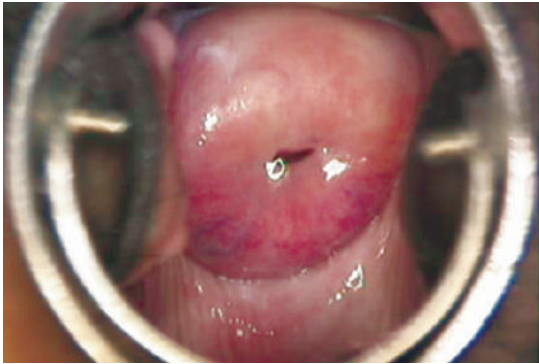
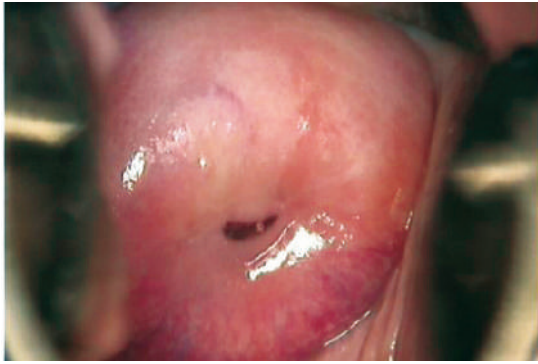




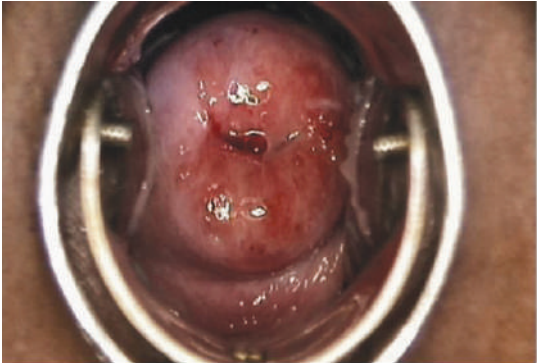
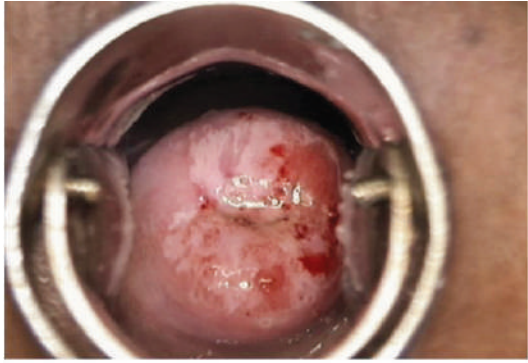
6.14 Detecting lesions with acetic acid

In order to visualize cervix with acetic acid, freshly prepared 5% acetic acid should be applied to the cervix and wait for 1 minute. Acetic acid causes reversible coagulation and precipitation of cellular proteins making the epithelium white and opaque. The amount of cellular proteins presents in the epithelium determine the effect of the acetic acid. The superficial layers of cells in the normal squamous epithelium are almost devoid of protein as the nuclei are very small, contain very little chromatin and the cytoplasm is replaced by glycogen. Therefore, when acetic acid is applied to the normal squamous epithelium, hardly any protein to coagulate and there is no change in colour. In CIN and invasive cancer where there is high cellular and nuclear protein due to the large number of undifferentiated cells in the epithelium, cells undergo maximal coagulation and produce acetowhite areas.

- **Before and after application of acetic acid: No acetowhite areas**

	
Figure 6.40 Before application of acetic acid	Figure 6.41 After application of acetic acid
Source: Training of health staff in colposcopy, LEEP and CKC - Trainees' handbook, World Health Organization,2017	

- **Before and after application of acetic acid: acetowhite area can be seen**

	
Figure 6.42 Before application of acetic acid	Figure 6.43 After application of acetic acid
Source: Training of health staff in colposcopy, LEEP and CKC - Trainees' handbook, World Health Organization,2017	

6.14.1 Conditions where acetowhite areas can be seen other than neoplasias

- Immature squamous metaplasia
- Healing and regenerating epithelium after an inflammation
- Leukoplakia (Hyperkeratosis)
- Condyloma

6.14.2 Differences of acetowhite areas in different situations

In CIN / cancer	Conditions other than CIN / cancer
More- dense	Less dense, pale and often translucent
Thick and opaque with well demarcated margins	Patchy with ill-defined margins
Restricted to transformation zone	Widely distributed in the cervix
Appears quickly and persists for > 1 minute	Quickly disappears, usually within 30 -60 seconds

Table 6.1 Differences of acetowhite areas in different situations
Source: Training of health staff in colposcopy, LEEP and CKC - Trainees’ handbook, World Health Organization,2017

6.15 Detecting lesions with Lugol’s Iodine

Glycogen containing epithelium take up Iodine due to the affinity of iodine to glycogen when apply Lugol’s Iodine. The squamous epithelium with normal glycogen content stain mahogany brown or black after application of Lugol’s Iodine. Conditions including CIN and invasive cancer, condylomas, columnar epithelium, immature squamous metaplastic epithelium, leukoplakic areas and inflammatory conditions of the squamous epithelium do not stain with Iodine solution. The reason is squamous epithelium contains little or no glycogen in these situations.

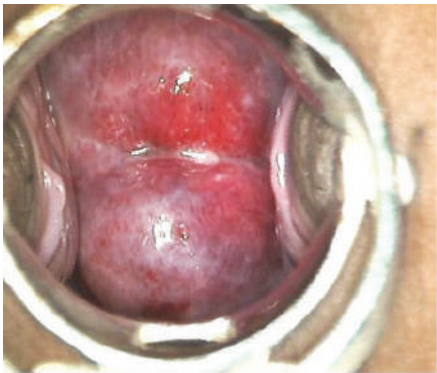

Figure 6.44 Before application of Lugol’s Iodine

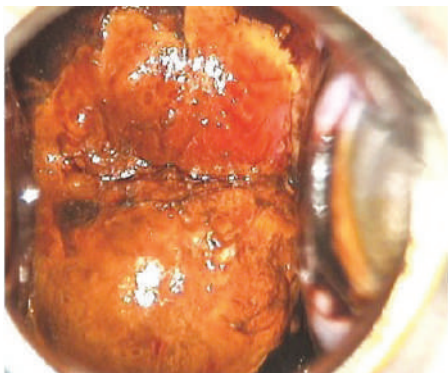


Figure 6.45 After application of Lugol’s Iodine


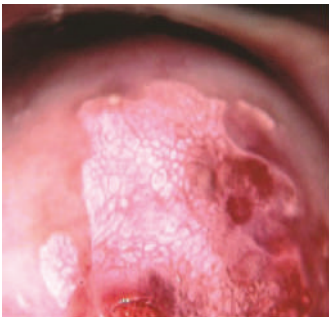

Source: Training of health staff in colposcopy, LEEP and CKC - Trainees’ handbook, World Health Organization,2017

6.16 Grade 1 and Grade 2 changes on colposcopy

6.16.1 Grade 1 changes on colposcopy

In grade 1 or minor abnormality, there is thin acetowhite area with irregular (feathered) or angular (geographical) margins with flat surface appearing in the transformation zone. Fine mosaic or fine punctations and satellite lesions situated away from the SCJ also comes under grade 1 abnormality. Grade 1 abnormalities can be seen in CIN 1 and also in immature metaplasia or condylomas.


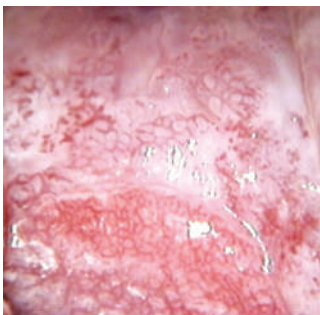
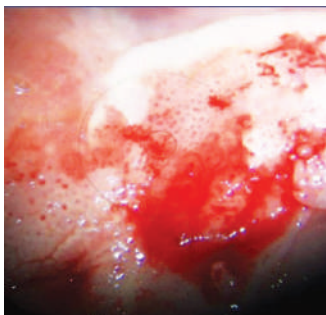
- **Appearance of Grade 1 changes on colposcopy**

		
Figure 6.46 Thin acetowhite area with irregular geographic margins	Figure 6.47 Fine mosaic pattern	Figure 6.48 Fine punctations
Source: Training of health staff in colposcopy, LEEP and CKC - Trainees' handbook, World Health Organization, 2017		

6.16.2 Grade 2 changes on colposcopy

The characteristic features of grade 2 abnormality on colposcopy is a dense acetowhite area on the TZ with well-defined flat or elevated regular margins. Vascular abnormalities like coarse mosaics and coarse punctations may be associated. Other features of grade 2 abnormalities are presence of cuffed crypt openings, inner border sign and ridge signs. In high grade lesions (CIN 2 / CIN 3), grade 2 abnormalities can be seen on colposcopy. The higher the grade of abnormality, the denser is the acetowhitening. In high grade neoplasia, acetowhite area appears quickly and persists for a longer time.

- **Appearance of Grade 2 changes on colposcopy**

		
Figure 6.49 Dense acetowhite area with sharp raised margins	Figure 6.50 Coarse mosaic pattern	Figure 6.51 Coarse punctuation
Source: Training of health staff in colposcopy, LEEP and CKC - Trainees' handbook, World Health Organization, 2017		

6.17 Cuffed crypt opening

A normal crypt opening appears on colposcopy as a black dot surrounded by a thin rim of acetowhite line in the TZ. When the crypt opening is large, there is prominent, dense acetowhite rim which is raised from the surface (like a doughnut) and it is named as “cuffed crypt opening”. Usually cuffed crypt opening is located in the dense acetowhite area, but may be isolated also. Presence of cuffed crypt openings indicate extension of the neoplasia inside the crypt and are usually associated with high grade lesions.

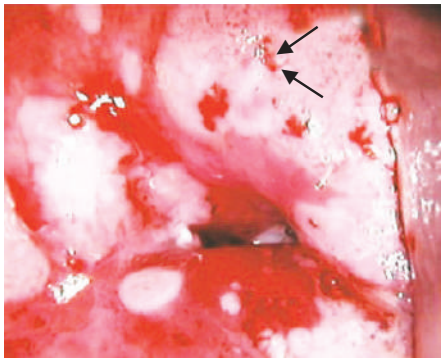
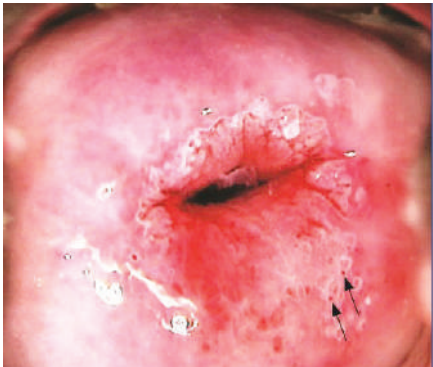
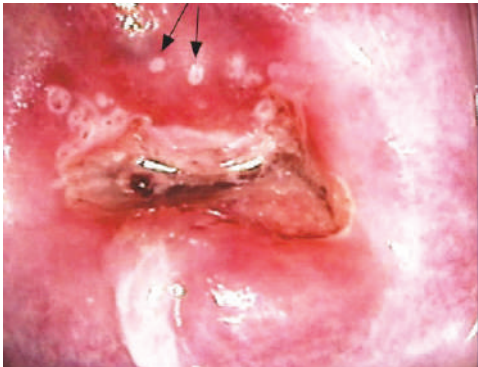
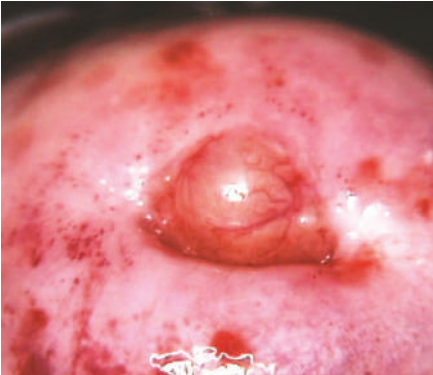



Figure 6.52 Cuffed crypt openings
Source: Training of health staff in colposcopy, LEEP and CKC - Trainees’ handbook, World Health Organization,2017

	
Figure 6.53 Crypt opening seen on the posterior lip of the cervix	Figure 6.54 Crypt openings on the anterior lip of the cervix
Source: Training of health staff in colposcopy, LEEP and CKC - Trainees’ handbook, World Health Organization,2017	

	
Figure 6.55 Nabothian cyst seen as a blister on the anterior lip of the cervix	Figure 6.56 Multiple Nabothian cysts on the anterior lip of the cervix
Source: Training of health staff in colposcopy, LEEP and CKC - Trainees’ handbook, World Health Organization,2017	

6.18 Ridge sign

Characteristic features of Ridge sign are thick and elevated acetowhite area which is projected near the SCJ as the top of a wall or ridge. Appearance of ridge sign indicates the presence of a high grade lesion.

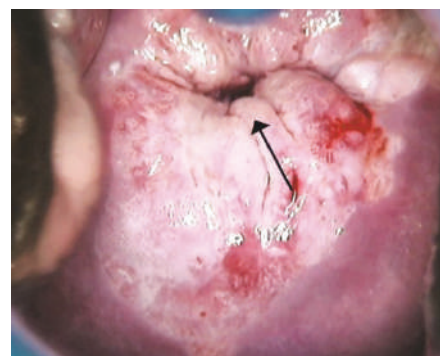


Figure 6.57 Ridge sign

Source: *Training of health staff in colposcopy, LEEP and CKC - Trainees' handbook*, World Health Organization, 2017

6.19 Inner border sign

When a low grade and high grade lesions co exist, there may be internal margins due to the abrupt change in the nature of the lesion(s). This is called “lesion within a lesion” or “inner border sign”. It is a feature of high grade neoplasia, with the inner, more proximal lesion being more severe.

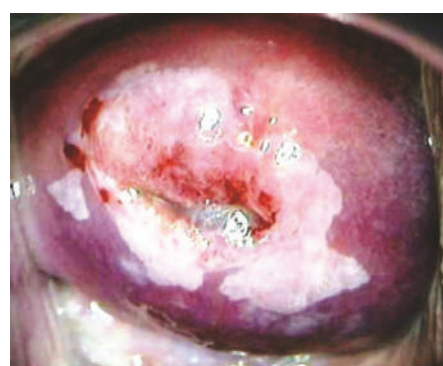


Figure 6.58 Inner border sign – lesion at 7 o' clock position is more dense than the surrounding lesion

Source: *Training of health staff in colposcopy, LEEP and CKC - Trainees' handbook*, World Health Organization, 2017

6.20 Features suggestive of invasive cancer

Invasive lesions can be having any of the following features:

- Growth or ulcer with necrotic areas
- Dull dense acetowhite area on the TZ; usually large
- Acetowhite area with raised well demarcated margins and the surface is elevated at places
- Atypical vessels (bizarre shapes, no definite branching patterns, unequal thickness along the stem, often raised from the surface, shiny and easily bleed at touch)

- Coarse mosaic, coarse punctuation or combinations of these
- Erosion of the surface that bleeds easily
- Uniform Iodine negative area

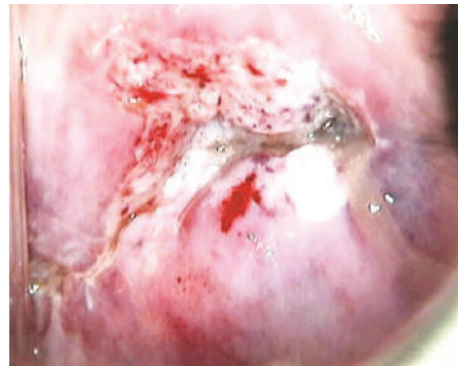


Figure 6.59 Early Invasive cancer

Source: Training of health staff in colposcopy, LEEP and CKC - Trainees' handbook, World Health Organization, 2017

6.21 Features of Adenocarcinoma in situ and Adenocarcinoma

If there is a dense acetowhite area on the columnar epithelium that is persistent for a long time, a glandular lesion should be suspected. Grated coconut appearance of adenocarcinoma in situ is due to the multiple dense acetowhite areas seen on the columnar epithelium.

The irregular dense acetowhite area on the columnar epithelium with abnormal blood vessels can be seen in adenocarcinoma.

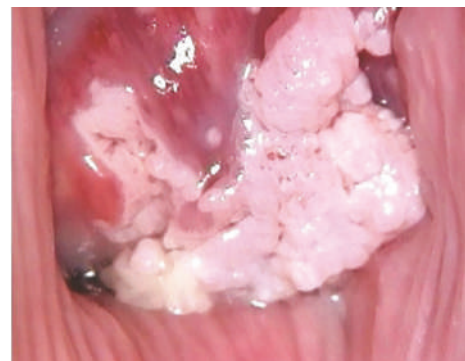

Figure 6.60 Adenocarcinoma

Source: Training of health staff in colposcopy, LEEP and CKC - Trainees' handbook, World Health Organization, 2017

6.22 Interpretation according to Swede score

Swede score is calculated based on five variables to interpret the findings after completion of colposcopy. Assign 0, 1 or 2 points for each variable and the sum of the points will be calculated. This will help to arrive at a diagnosis and decide further management. If Swede score is less than 5, there is no need of biopsy because it indicates that the probability of neoplastic lesion is very low. A score between 5 -7 is usually seen in low grade lesions or condylomas (HPV induced benign lesions). High grade intraepithelial lesions or cancers usually have scores of 8 and above.

The provisional colposcopic diagnosis of normal, LSIL, HSIL, adenocarcinoma in situ or invasive cancer is made after taking into consideration the IFCPC grade of the findings and the Swede score.

6.22.1 Swede scoring system for colposcopic diagnosis

	Score 0	Score 1	Score 2
Acetic acid uptake	Zero or transparent	Thin, milky	Distinct, stearin
Margin & surface	Zero or diffuse	Sharp but irregular, jagged, geographical, satellites	Sharp and even different in surface levels including cuffing
Vessels	Fine, regular	Absent	Coarse and atypical vessels
Lesion size	< 5mm	5 – 15 mm or two quadrants	>15 mm or three to four quadrants or endocervically undefined
Iodine staining	Brown	Faintly or patchy yellow	Distinct yellow
<p>Table 6.2 Swede scoring system for colposcopic diagnosis Source: <i>Training of health staff in colposcopy, LEEP and CKC - Trainees’ handbook, World Health Organization, 2017</i></p>			

6.23 Documentation of colposcopic findings


General assessment		Adequate/inadequate (reason) SCJ visible: completely/partially/not visible Transformation zone: 1/2/3	
Normal colposcopic findings		Original squamous epithelium Mature Atrophic Columnar epithelium Ectopy Metaplastic squamous epithelium Nabothian cysts Crypt opening	
Abnormal colposcopic findings	General principles	Location of the lesion: inside TZ / outside TZ / both inside and outside TZ: <ul style="list-style-type: none"> • Clock position (please mark below) • Number of quadrants involved • Size of lesion: <25% / 25 – 50% / 50-75% / >75% 	
	Grade 1 (minor)	Thin AW epithelium Irregular, geographic border	Fine mosaic Fine punctuation
	Grade 2 (major)	Dense AW epithelium Rapid appearance of acetowhitening Cuffed crypt opening	Coarse mosaic Coarse punctuation Sharp border Inner border sign Ridge sign
	Non specific	Leukoplakia Erosion Lugol's staining (Schiller's test): stained / non-stained	
Suspicious for invasion		Atypical vessels / fragile vessels / irregular surface / exophytic lesions / Necrosis / ulceration (necrotic) / Tumour / Gross neoplasm	
Miscellaneous findings		CTZ Condyloma Polyp Inflammation	Stenosis Congenital anomaly Post - treatment

Table 6.3 Documentation of colposcopic findings
 Source: Training of health staff in colposcopy, LEEP and CKC - Trainees’ handbook, World Health Organization, 2017

CHAPTER 7

DIAGNOSIS AND TREATMENT FACILITIES

7.1 Punch biopsy

A circular blade (like a paper hole puncher) is used for this procedure to remove tissue samples. Using this, one or more biopsies can be taken from different areas of the cervix.

7.1.1 Purpose of cervical punch biopsy

- To confirm the presence of pre - cancerous lesion (CIN) or cervical cancer detected by a pap smear
- To evaluate a suspicious vaginal or cervical lesion identified during pelvic examination
- To monitor women receiving conservative treatments for pre-cancerous lesion

7.1.2 Timing of punch biopsy

Punch biopsy should be performed a week after the end of menstruation because menstrual blood will obscure the view of cervix.

Questions to be asked from the woman before performing colposcopy and punch biopsy

- Whether the woman is pregnant
- Any allergies to medications
- Any bleeding disorder or taking anticoagulant or antiplatelet drugs

- Advise the woman not to apply vaginal creams or medications for 24 hours prior to the procedure
- Empty her bladder before the procedure

7.1.3 Procedure of the colposcopy directed punch biopsy

- Low power magnification is used to obtain a panoramic view of the cervix.
- Biopsy site is selected from the area with maximum disease severity.
- If the lesion spreads in different areas, multiple biopsies should be taken.
- The posterior cervical lip is sampled first to prevent obscuring as a result of the bleeding.
- Biopsy forcep is placed straight over the lesion to be biopsied.
- The opened biopsy forcep is positioned in such a way that the fixed jaw end of the forceps is placed close to or within the os.
- When a biopsy taken from the posterior lip, the biopsy instrument handles are hold upside down.
- Cervix need to be pushed backwards with the open biopsy forceps as much as possible in order to prevent slipping of the forceps from biopsy site.
- Forceps handles are squeezed together immediately while asking the patient to cough.
- Jaws of the forceps are locked and handed over to the assistant for further proceedings.
- Confirm colposcopically whether the intended area has been sufficiently sampled.
- Haemostasis should be achieved by applying Monsel's paste for 30 - 60 seconds.
- Endocervical curettage may be performed after colposcopy directed biopsy if;
 - SCJ is not completely visible.
 - Lesion extends into the endocervical canal.

7.1.4 Risk and complications of punch biopsy

Rare complications associated with cervical punch biopsy include,

- Excessive bleeding for up to a week after the procedure
- Infection
- Mild cramping
- Vaginal soreness
- Dark discharge for 1- 3 days

7.1.5 Advices to be given to the patient after doing the punch biopsy

- Avoid strenuous activities for 8 – 24 hours.
- Avoid sexual intercourse, douching and tampons for several days to one week until the biopsy sites have healed.
- Mild cramping after a biopsy is normal and take pain killers.
- Slight bleeding may also be normal after biopsy and use sanitary napkins rather than tampons.
- Inform the doctor immediately if heavy bleeding or vaginal discharge persists for more than 21 days.

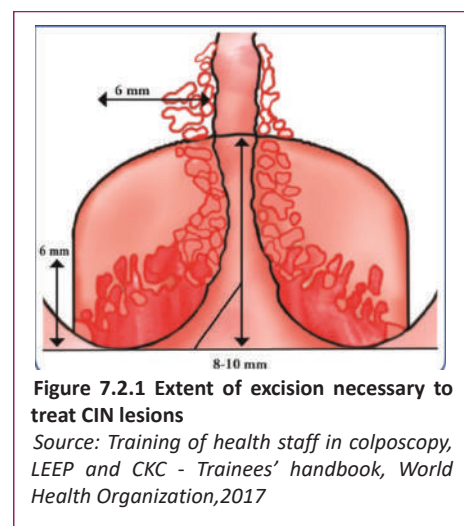
7.2 Loop Electrosurgical Excision Procedure (LEEP/LLETZ)

7.2.1 Principles of LEEP

LEEP is an excisional method used to treat cervical intraepithelial neoplasia. A wire loop electrode powered by an electrosurgical unit is used to remove the entire transitional zone along with the lesion. The heat generated from a high voltage electrical arc between the operating electrode and tissue allows the operator to cut by vaporizing the tissue. A mix of cutting and coagulation current is used for this purpose. Removal of entire TZ treat the lesion effectively and provide a specimen for detailed histological evaluation.

The appropriate size of the loop should be chosen to achieve adequate depth and width of the cut depending on the size and position of the lesion. Usually the width of the loop ranges from 10 mm to 20 mm and the depth ranges from 10 mm to 15 mm.

Since the disease can extend along the crypts of the TZ and the average depth of a crypt is 5 mm, the extent of excision should be at least 8 mm to 10 mm to get an adequate disease-free margin.



7.2.2 Different types of excision

The type of excision depends on the type of TZ and the nature and extent of the lesion.

7.2.2.1 Type 1 excision

Type 1 excision is adequate for CIN 2/3 lesions if the TZ is type 1 (SCJ is fully visible on the ectocervix). In type 1 excision, it is not necessary to include much of the endocervical canal.

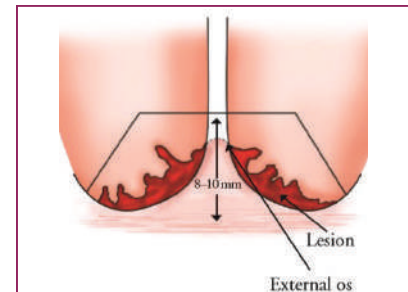


Figure 7.2.2 Type 1 excision

Source: *Training of health staff in colposcopy, LEEP and CKC - Trainees' handbook*, World Health Organization, 2017

7.2.2.2 Type 2 excision

This type of excision needs for excision of type 2 TZ. Depending on the extent of the lesion inside the endocervical canal, endocervical component of the TZ should be included. Type 2 excision is suitable for CIN 2/3 lesions extending to the endocervical canal and the upper margin of the lesion can be seen clearly.

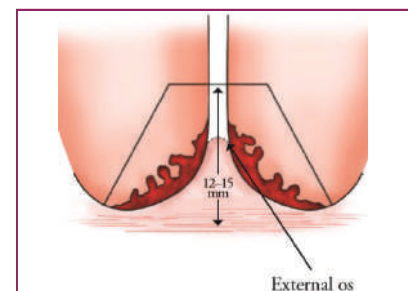


Figure 7.2.3 Type 2 excision

Source: *Training of health staff in colposcopy, LEEP and CKC - Trainees' handbook*, World Health Organization, 2017

7.2.2.3 Type 3 excision

This type of excision involves excision of type 3 TZ and significant amount of endocervical canal is excised (1.5 to 2 cm) as the upper limit of the lesion or the TZ is not visible. Type 3 excision is required for CIN 2/3 lesions with type 3 TZ or glandular lesion or micro invasive cancer.

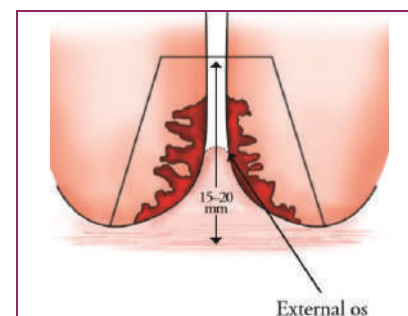


Figure 7.2.4 Type 3 excision

Source: *Training of health staff in colposcopy, LEEP and CKC - Trainees' handbook*, World Health Organization, 2017

7.2.3 Indications for LEEP

- CIN of any grade
- Lesions not amenable to treatment by ablative techniques
- Discordance between cytology, colposcopy & punch biopsy
- Glandular abnormality on cytology, punch biopsy or endocervical curettage
- Treatment failures (after ablative or excision procedure)

7.2.4 Instruments needed for LEEP

- Examination table with leg support
- Focusing light for examination
- Smoke evacuator with tubing for attachment to speculum
- Colposcope
- Electrosurgical unit (with patient return electrode, hand switch or foot operated switch)
- Loop/ball electrodes
- Insulated self-retaining speculum with smoke extraction channel
- Sponge holding forceps
- Lateral vaginal wall retractor
- Kidney tray
- Syringe for injecting local anaesthetic (dental syringe preferred)

7.2.5 Consumables required for LEEP

- Gloves (sterile/gloves after high-level disinfection (HLD))/disposable)
- Sterile cotton swabs, cotton swab sticks
- Normal saline
- Freshly prepared 5% acetic acid
- Lugol's Iodine
- Monsel's paste
- Local anaesthetic (1 or 2 % lignocaine) with or without 1:100 000 epinephrine
- Lubricant jelly
- Vials containing 10% formaldehyde
- Waste disposal bag
- Chlorine solution (0.5%) or 2% glutaraldehyde
- Case record form

7.2.6 Requirements for LEEP

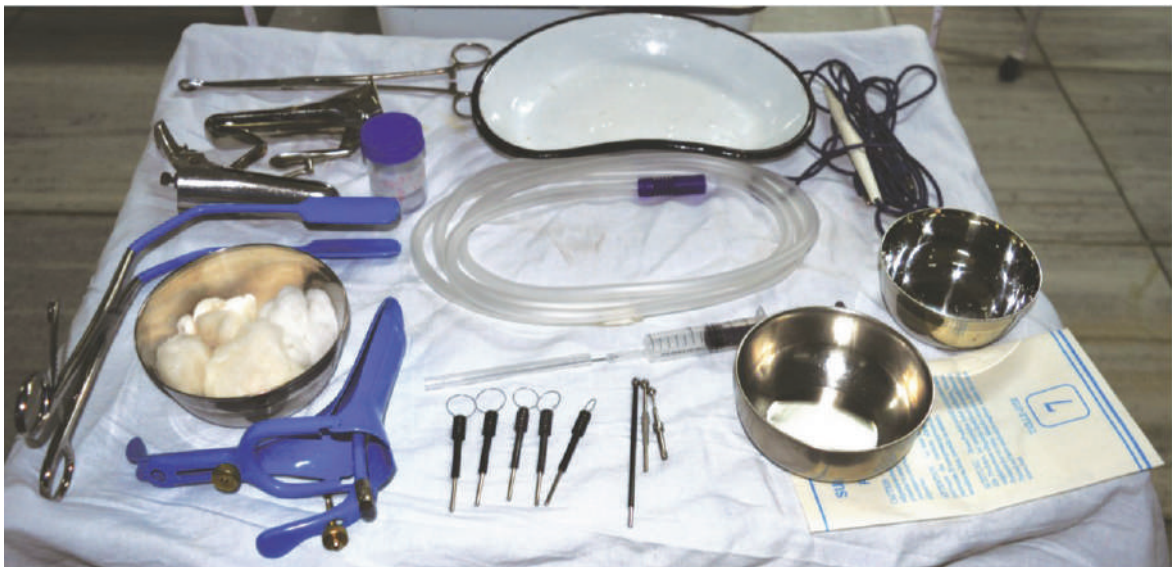

Figure 7.2.5 Requirements for LEEP
Source: Training of health staff in colposcopy, LEEP and CKC - Trainees’ handbook, World Health Organization,2017

7.2.7 Procedure of LEEP

- Patient is placed in a dorsal lithotomy position.
- A reusable patient return electrode is placed under buttock or on thigh and is connected to electro-surgical unit.
- An appropriate sized insulated speculum is inserted with smoke extraction channel to visualize cervix.
- Colposcopic assessment is performed.
- Local anesthetic is infiltrated into stroma of ectocervix (subepithelial) at the periphery of the lesion.
- Electrosurgical unit is set at 50-50 blended current.
- Based on size and endocervical extent of lesion, an appropriately sized loop should be selected.

7.2.8 Advantages & disadvantages of LEEP

Advantages	Disadvantages
Simple outpatient procedure	Electricity required
High efficacy	Requires more skill than ablative techniques
Tissue available for histological evaluation	Small risk of bleeding
Can be performed under local anaesthesia	Small risk of adverse obstetric outcome
Minimal complications	Expensive compared to cryotherapy unit

Table 7.2.1 Advantages and disadvantages of LEEP
Source: Training of health staff in colposcopy, LEEP and CKC - Trainees’ handbook, World Health Organization,2017

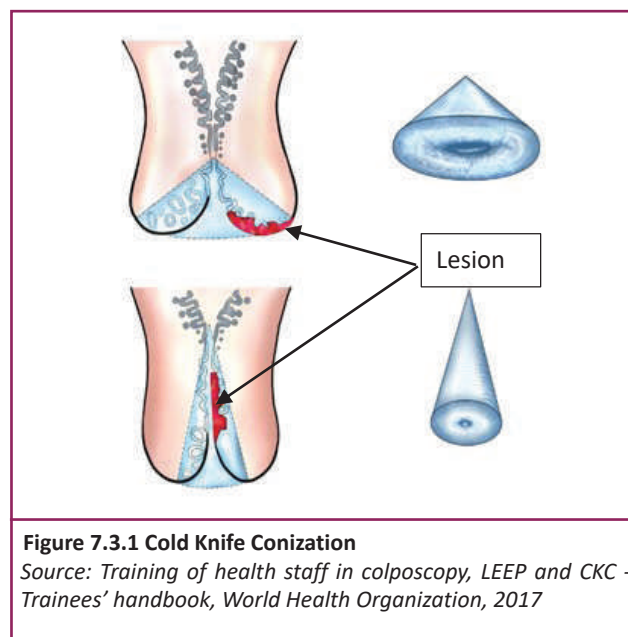
7.2.9 Complications of LEEP

- Excessive bleeding during or immediately after surgery
- Secondary hemorrhage due to post-operative infection
- Post-operative infection
- Pelvic Inflammatory Disease(PID)
- Cervical stenosis
- Cervical incompetence
- Premature rupture of membrane
- Preterm labour in subsequent pregnancies

7.3 Cold Knife Conization

7.3.1 Principles of CKC

- A cone shaped portion of cervix is removed by a knife
- This removes both ectocervix and endocervix to ensure removal of entire TZ & lesion
- Extent and disease severity determines the width and the length of cone



7.3.2 Indications for CKC

- Adenocarcinoma in situ on punch biopsy
- Microinvasive cancer on punch biopsy

7.3.3 Contraindications for CKC

- Pregnancy
- Severe infection/inflammation of cervix
- Less than 2 months postpartum

7.3.4 Instruments / Equipment required

- Operation table with stirrups
- Focusing light for examination
- Electrosurgical unit (with patient return electrode, hand switch or foot plate)
- Ball electrodes
- Posterior vaginal speculum
- Sponge holding forceps
- Single tooth tenaculum
- Kidney tray
- Number 11 scalpel with blade
- Needle holder
- Syringe for injecting vasoconstricting agents on cervix (Dental syringe preferred)

7.3.5 Consumables required

- Gloves (sterile/gloves after high-level disinfection/disposable)
- Sterile cotton swabs, cotton swab sticks
- Lugol's Iodine
- Monsel's paste
- Local anesthetic (1 or 2 % xylocaine/lidocaine) with 1:100,000 epinephrine
- Suture (2-0 polyglactin with needle)
- 5 mm ball electrode
- Lubricant jelly
- Vials containing 10% Formaldehyde
- Waste disposal bag
- Chlorine solution (0.5%) or 2% Glutaraldehyde
- Case record form

7.3.6 Requirements for CKC

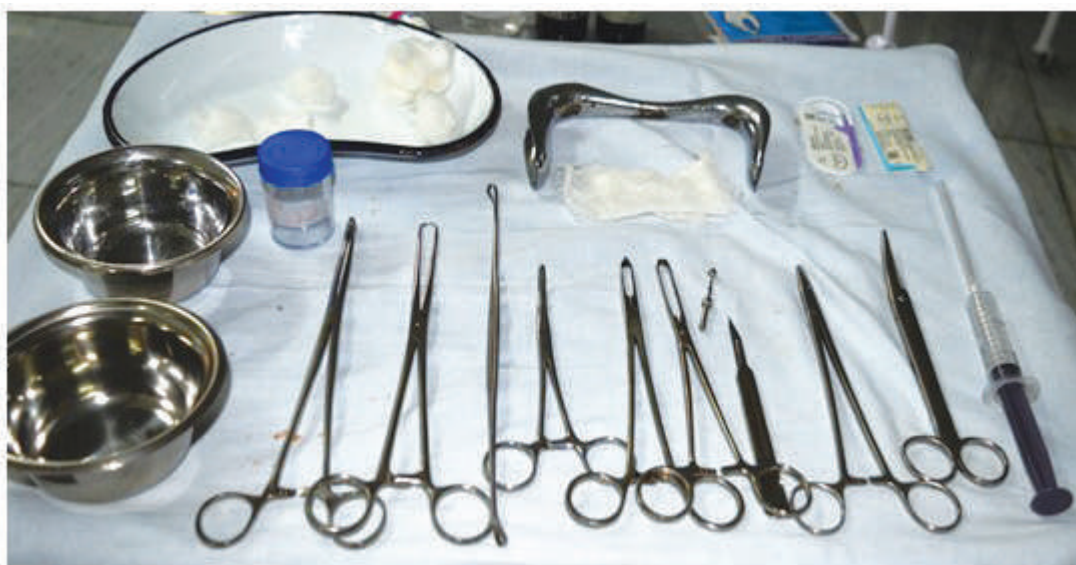

Figure 7.3.2 Requirements for CKC

Source: *Training of health staff in colposcopy, LEEP and CKC - Trainees' handbook*, World Health Organization, 2017

7.3.7 Procedure of CKC

- Patient is placed in dorsal lithotomy position
- Patient return electrode is placed under buttock or on thigh and is connected to electrosurgical unit
- Vulva, vagina and perineum is cleaned with antiseptic solution & drape the patient
- Appropriately sized speculum is inserted and cervix is exposed
- Anterior lip of the cervix is grasped with a tenaculum
- 5-10 ml solution of 2% lignocaine & epinephrine in a concentration of 1:200,000 is injected into ectocervical stroma (sub-epithelial)
- Surgical blade number 11 is used to make a circular incision starting at 12 o'clock on cervix
- Tip of blade is angled towards endocervical canal till about 15–20 mm of endocervix is resected
- Excised tissue is removed with a pair of forceps
- The defect is fulgurated with ball electrode using pure coagulation current
- Endocervical curettage is performed
- Monsel's paste is smeared on treated area

7.3.8 Advantages & disadvantages of CKC

Advantages	Disadvantages
Margin can be evaluated better for complete excision	General or regional anaesthesia required
Invasive cancer can be detected or ruled out by histological evaluation	Requires highly skilled provider
High efficacy	Needs hospitalization and use of operating room
	Higher risk of bleeding during and after surgery
	Higher risk of cervical incompetence and preterm delivery

Table 7.3.1 Advantages and disadvantages of CKC
Source: Training of health staff in colposcopy, LEEP and CKC - Trainees’ handbook, World Health Organization, 2017

7.3.9 Complications of CKC

- Excessive bleeding during or immediately after surgery
- Secondary hemorrhage due to post-operative infection
- Post-operative infection
- PID
- Cervical stenosis
- Premature rupture of membrane
- Preterm labour in subsequent pregnancies

Refer flow chart in ANNEX III to select the appropriate management

CHAPTER 8

COUNSELLING AND ADVICE AFTER TREATMENT

8.1 Pre-counselling before the procedure

Counselling is a crucial component in cervical cancer screening, colposcopy and treatment. Women should be educated and informed regarding the procedures so that they can take informed decisions.

Since most of the women do not have any symptoms, they are reluctant to undergo procedures and treatments and also embarrassed and anxious to undergo gynecological checkups, tests and procedures.

Therefore, counselling is very much needed to empower the woman to take decisions and understand the importance of undergoing further investigations and treatments. It will further motivate the women for future follow ups and warrants compliance to services.

Following are some of the facts need to be dealt with the women attending to the clinic.

Explain ;

- Reasons for the procedure and its importance in preventing cervical cancer
- Detailed explanation of the examination procedure
- Discomfort that may be experienced during and after the procedure
- The treatment requirement if necessary and the treatment modalities available
- Possible complications during the procedure and in relation to the treatment
- Consequences of not being tested and treated
- Requirement of her consent for the procedure

8.2 Counselling and advice after LEEP

- Woman should be informed about the possible and expected symptoms after the procedure
eg: watery or blood-stained discharge which may persist up to 4 weeks
- She should be advised to wear sanitary napkins to avoid staining of clothes
- Abstain from sexual intercourse for about 4 weeks or use condoms if it cannot be avoided
- Return in one month for checkup when the histology report also will be available
- If she is having any of the following symptoms she should return immediately

- ▶ Fever more than 2 days
- ▶ Foul smelling and purulent vaginal discharge
- ▶ Severe lower abdominal pain or cramps
- ▶ Heavy vaginal bleeding (heavier than menstrual bleeding)

Post treatment counselling and advice after CKC is same as for LEEP.

CHAPTER 9

FOLLOW UP

Follow up after treatment of CIN

Any of the treatment methods are not 100% successful. Therefore, proper follow up of patients after the treatment is essential. A small proportion of women (<10%) who treated will have residual CIN. According to the published literature, women who have been treated for cervical pre-cancer lesions are much more likely to develop cervical cancer than women who do not have cervical pre-cancer.

According to the case series studies, more than 50% of cancers are in women who are lost to follow up. The same study demonstrated that women aged 50 years or older are particularly at risk of persistent/recurrent disease.¹⁰

It is necessary to follow up with cervical smear and colposcopic examination at relatively frequent intervals for 1-2 years before being returned to routine screening in the community, because treated women have a 2-5 fold increased risk of developing cervical cancer compared with the general population.⁸ Much of this increased risk is attributed to lost to follow up.^{9,11}

Women with positive margins at histology (incomplete excision) have a 6 fold increased risk of residual disease.¹⁰

Women with a large type 2 or type 3 TZ have a 3 fold increased risk of having incomplete excision, need longer follow up than those who have complete excision.

Women should be followed up at 12 months after the LEEP procedure and at 6-12 months after the CKC as mentioned below.

1. Women should undergo a screening test - HPV testing / Pap smear test (whichever screening test is available). Co-testing with both is better than one test.
2. Perform colposcopy.
3. Should take biopsies from abnormal areas (If present).
4. Residual or recurrent lesions should be treated again with proper treatment methods.

Key Points

- Follow up of patients treated with colposcopy is essential.
- Women treated for suspected cervical pre cancer have 2-5% increased risk of developing cervical cancer compared to general population.
- There is no treatment method with 100% success rate.
- Risk is increased if,
 - There are positive margins at histology
 - Age >50 years at the time of treatment
 - Positive HPV DNA test after treatment
- Lost to follow up is a major cause for development of cancer after treatment
- Co-testing with cytology and oncogenic HPV is a better method of monitoring women after treatment

CHAPTER 10

CASE BASED DISCUSSIONS

10.1 Colposcopy in pregnancy

The management of the abnormal smear in pregnancy remains a challenge to the modern colposcopist. Colposcopy in pregnancy is difficult. Anatomic variants can mimic disease. Significant cytologic overall detection of LSIL demands an increased understanding of physiologic variants in pregnancy. Possible recent increases in cervical cancer incidence in younger women requires comprehensive knowledge of warning signs of early invasion. Modern management approaches must temper the need for accurate exclusion of cancer with the risk of overly aggressive interference in patients without disease or with very minor atypia.

If the patient is already pregnant and is due to have a cervical screening test, patient can wait to have the test until 3 months after delivery.

If the patient had an abnormal result from a cervical screening test, she may need to have a screening test while she is pregnant. Colposcopy is a safe procedure during pregnancy.

10.1.1 Treatment for abnormal cells during pregnancy

- **Before giving birth**

For CIN 1 (Low grade) - No need to have any treatment until around 3 months after delivery. After that, patient can be offered to have another colposcopy to check the cervical cells again. In many women with mild changes, they go back to normal without any treatment.

For CIN 2 or 3 (High grade) - She can be offered another colposcopy when she is 6 months pregnant to keep an eye on them. The abnormal cells are not likely to change much over the time of pregnancy.

For suspicious lesions, biopsy should be performed very carefully.

- **After giving birth**

If the changes have not gone back to normal after the delivery, woman should be treated.

10.2 Colposcopy in HIV positive patients

Screening for cervical cancer is of particular importance for women and adolescent girls infected with HIV. The incidence of CIN, as confirmed by colposcopy, is four to five times higher in HIV-infected women and adolescents compared to HIV-negative women and adolescents with high-risk sexual behaviours.

(annual pap smear is need to be carried out for HIV positives)

Cervical cancers are common in HIV-infected women because;

- Both HIV and HPV are sexually transmitted
- HIV-infected women are more likely to have persistent HPV infection
- People with resistant infection with one or more oncogenic HPV subtypes is a major factor in the pathogenesis of premalignant and malignant cervical disease

All women newly diagnosed with HIV should have cervical surveillance performed by or in conjunction with the venereology team managing the HIV infection. Annual cytology should be performed with an initial colposcopy. Subsequent colposcopy for screening abnormality should follow national guidelines.

CHAPTER 11

MONITORING AND EVALUATION

Monitoring and evaluation is a very important component of any systematically conducted programme. In order to have information on services provided in the clinic, type of procedures carried out, pathological conditions and number of women attended need to be documented. For this purpose, a colposcopy clinic register should be maintained in all colposcopy clinics. The National Cancer Control Programme which is the national focal point for prevention and control of cancers in the country collect information on quarterly basis from all colposcopy centers.

11.1 Documents attached

1. Colposcopy clinic register
2. Quarterly colposcopy return
3. Consent form for colposcopy

2. Quarterly return on provision of colposcopy services by health institutions

This return should be compiled by a responsible officer (Nursing Officer in charge of colposcopy centre) and be sent to the National Cancer Control Programme, 555/5, Public Health Complex, Elvitigala Mw, Narahenpita on a quarterly basis. Arrangements should be made to send the return on or before 10th day of the month subsequent to each quarter. (Ex: the return of the 1st quarter should be received by the NCCP on or before 10th April)

Quarter:	1 st (Jan-March)	2 nd (April-June)	3 rd (July- Sept)	4 th (Oct-Dec)
----------	-----------------------------	------------------------------	------------------------------	---------------------------

Name of the Institution: Unit:
Number of Colposcopes available: Analog: Digital:
Number of properly functioning Colposcopes: Analog: Digital:
If the Colposcopes are not functioning properly, state the reason/reasons:
.....

Number of colposcopy procedures conducted during the last quarter:

Month	Number of clients			Cryotherapy	LEEP	Biopsy	Other
	Number of clients Referred by MOH with abnormal pap smear	Number of clients not referred by MOH	Total number of clients undergone colposcopy				

Any Comments:

Name of the officer compiling the return: Date:
Designation:
Name of the Head of the Institution:
Signature of the Head of the Institution:

3. **Consent form for colposcopy**

I acknowledge that Dr. has explained the colposcopy procedure to me and has answered satisfactorily to my questions.

I hereby consent to colposcopy and biopsy (If necessary).

..... Name Signature Date
..... Witness' name Witness' signature Date

CHAPTER 12

STANDARD OPERATING PROCEDURE – COLPOSCOPY

1. Definition of colposcopy

Colposcopy is a procedure undertaken to examine the uterine cervix (vagina, vulva too) in a magnified field to recognize suspicious abnormal areas. A high powered microscope (Colposcope) is used for this purpose.

2. Indications for colposcopy

- Patients with abnormal cells on pap smear
- Genital warts
- Other suspicious genital lesions

3. Precautions/Contraindications

- Active Gonorrhoea /or Chlamydia
- Non - cooperative patient
- Pregnancy
- Heavy menstruation

4. Clinic Setting

The clinic environment should be welcoming and facilitating to protect the patient's dignity. Patients should be given time to discuss their care before and after the colposcopy examination and/or treatment.

Colposcopy clinic ideally should consist of;

- Registration area
- A private area with changing facilities
- Toilet facilities
- A permanently sited specific room for colposcopy
- Separate waiting and recovery area

5. Colposcopy clinic staff

Colposcopy clinic staff must be appropriately qualified and experienced. Colposcopy must be performed by a trained colposcopist, who works closely with other health professionals including pathologists (there must be a formal arrangement for consultation with a pathologist, if there is no dedicated one on site).

Note: Colposcopists under training must be supervised by an experienced colposcopist.

In addition to the colposcopist, there should be a specially trained nurse attendant who should be able to assist the colposcopist and provide support to the patient.

The role of nurse attendant is to;

- Support the patient during the examination
- Ensure easy access to and availability of equipment during the examination
- Aid with camera adjustment, recovery of the patient
- Filling forms and processing specimens

6. Instruments needed to carry out colposcopy procedure

- Binocular Colposcope or digital Colposcope
- Cords/wires for connecting the Colposcope with electrical source, extension boards
- Instrument tray for colposcopy
- Kidney tray
- Galipot/small bowls (minimum 3)
- Self-retaining vaginal specula
- Vaginal side-wall retractor
- Sponge-holding forceps
- Endocervical speculum

- Endocervical curette
- Punch biopsy forceps
- Gloves (sterile/gloves after high-level disinfection/disposable)
- Cotton swabs (made of clean cotton, need not be sterile), cotton swab sticks
- Normal saline
- Dilute acetic acid (5%) solution (freshly prepared)
- Lugol's Iodine
- Monsel's solution/paste
- 10% formaldehyde
- Lubricant jelly
- Vials for biopsy samples

7. Preparation for colposcopy

- Keep necessary instruments ready
- Check availability of consumables
- Ensure that the Colposcope is functioning and is ready to use
- Position the Colposcope and check for adequacy of intensity of light source
- Adjust the eye pieces to get well-focused stereoscopic vision
- Arrange instruments and supplies on high-level disinfected tray or container

8. History taking

- Personal information
 - Name
 - Age
 - Address
 - Telephone number
 - LRMP
- Obstetric and Gynecological history
- History of pap smear

9. Procedure

- Explain the woman about the procedure.
- Ensure that the patient has understood and given informed consent.
- Explain the woman how the procedure will be performed using the colposcopy machine.
- Ensure that the woman has emptied her bladder.
- Arrangements should be made to maintain privacy using curtain stand or separate room for examination.
- Nursing officer or the assistant should help the woman to get onto the examining table and be comfortable on the examination table, help her to undress and prepare for a gynaecological examination.
- Hands of the colposcopist should be washed thoroughly with soap and water and dried with clean, dry cloth or air dry.
- New pair of examination gloves need to be worn on both hands.
- Check external genitalia to see any discharges from urethral opening.
- Appropriate sized speculum needs to be chosen and lubricate the blades with lubricant jelly or saline.
- Insert speculum and adjust appropriately to see the entire cervix.
- Fix the speculum blades in open position so that the speculum will remain in place with the cervix in view.
- Make sure the posterior fornix (vaginal space surrounding the ectocervix) is dry.
- Appropriate magnification should be used to bring the cervix in sharp focus (usually 6x or 8x).
- Colposcopy will be inadequate, if the cervix cannot be exposed properly or is obscured by excessive inflammation or bleeding or scar.
- Cervix should be examined for cervicitis, growths, ulcers and/or contact bleeding.
- If there are mucus or discharge, normal saline should be applied to the cervix with cotton swabs and gently remove them.
- External os and the SCJ should be located.
- Examine blood vessels with the help of a green (or blue) filter. If necessary, increase magnification.
- Apply a clean swab soaked in 5% acetic acid to the cervix.
- Need to look for any acetowhite changes in the cervix after a minute.
- SCJ need to be located again to determine the type of TZ.

- If acetowhite area is present, look for the following features:
 - ▶ Density
 - ▶ Margin characteristics
 - ▶ Location in relation to SCJ or external os
 - ▶ Number of quadrants involved
 - ▶ Vascular pattern
- If necessary, use an endocervical speculum to visualize the endocervix.
- Use a fresh swab to remove any remaining acetic acid from the cervix and the vagina after completion of the examination.
- Then apply Lugol's Iodine and inspect for colour changes in the cervix.
- Interpret colposcopic findings using the Swede score
- Depending on the Swede score, you may need to perform cervical biopsies or proceed for treatment.
- If punch biopsy needs to be performed, take biopsy/s from the worst identified lesion (s) close to the SCJ.
- In order to control bleeding, apply Monsel's solution (paste) to biopsy site and remove the speculum.
- Help the woman to get off from the examination table.
- Tell the woman about the importance of returning for further investigations and treatments as requested.

10. Resuscitation trolley

The need of resuscitation should be considered in the centers providing colposcopy services.

There should be a defibrillator and the trolley containing accessories for airway, breathing and circulation management, medications, IV fluids and infusion sets etc. in sufficient amounts for emergency management.

Regular check-ups need to be done to ensure the availability of contents in the resuscitation trolley.

11. Post colposcopy counselling

- Need to inform the woman about the colposcopy findings after the procedure.
- Ask the woman whether she is more comfortable discussing the test results while lying down or sitting up on the table.
- Inform the woman about the colposcopy findings and the significance of positive results.
- When positive findings are detected, reassure the woman saying that appropriate

treatment for the condition is available and arrangements will be made for that.

- Emphasize the importance of early treatment.
- When required, provide detailed and specific information about the referral center that she needs to visit for treatment.
- If a biopsy has been taken during colposcopy, information needs to be given to the woman when the biopsy report will be available.
- If she needs to clarify anything, encourage her to ask questions and respond with care.
- Provide necessary advices to take care of herself when she goes home;
 - ▶ Advise her to abstain from sexual intercourse until she is free from discharges or bleeding. If she has undergone LLETZ biopsy she needs to avoid sexual intercourse for a month.
 - ▶ Tampons should not be used for one month.
 - ▶ Avoid swimming or getting in to rivers, lakes etc. for 2 weeks.
 - ▶ She should be informed about the signs and symptoms that may occur due to complications.

Eg: Active bleeding, serious cramping or lower abdominal pain, pus-like discharge, fever etc.

If she experiences any of these, she needs to return to the centre or go to a hospital.
 - ▶ Give a specific date for the return visit when the laboratory reports also will be available. A follow-up visit should be planned preferably one month after the colposcopy.
- Biopsies need to be properly labelled before sending to designated pathology laboratories.
- If the colposcopist find something which he/she cannot handle, woman should be referred immediately to a higher level for further examinations or treatments (Gynaecologist).

12. Follow-up one month after the colposcopy

- Explain the woman about the findings of the laboratory report.
- Based on the lab results, she should provide proper advices regarding the follow-up that she will need.
- Pelvic examination should be done to check for healing.
- If necessary, she should be referred for further treatments or make an appointment for the next follow up visit.

13. Documentation

It is essential to document the findings in appropriate forms to record the colposcopic assessment.

The following information should be recorded.

- Reason for referral to colposcopy center
- Grade of cytological abnormality
- Was the examination adequate or inadequate – Entire cervix must be visualized in order to be adequate
- The presence or absence of vaginal and/or endocervical extension
- The colposcopic features of any lesion
- The colposcopic impression of the grade of the lesion
- The type of TZ, i.e. type 1,2 or 3
- If biopsies were taken, the sites from where they were taken

ANNEX I

INFECTION PREVENTION

1. Infection Prevention

Many infectious agents are transmitted by contamination with blood and/or body fluids and most infections can be spread before symptoms are present. Therefore, it is essential that healthcare workers take universal precautions (it is necessary to treat all clients and patients as infected). The following precautions need to be taken routinely by all healthcare workers.

- Wash hands thoroughly with soap and water before each examination.
- Client should be advised to wash her genital area, if possible, before the pelvic examination.
- High level disinfected or sterile instruments and a pair of surgical gloves (for both hands) need to be used always (if possible new examination gloves should be used alternative to HLD or sterile gloves).
- Waste material should be properly disposed (gauze, cotton and disposable gloves).
- Decontaminate instruments and reusable items immediately after use.
- After removing the gloves, hands need to be washed thoroughly with soap and water.

Steps of hand washing











1. Wet hands with water	2. Apply soap to cover hand surfaces	3. Rub hands palm to palm	4. Rub right palm over left dorsum with interlaced fingers and vice versa
			
5. Palm to palm with fingers interlaced	6. Rub backs of fingers to opposing palms with fingers interlocked	7. Do rotational rubbing of left thumb clasped in right palm & vice versa	8. Do rotational rubbing, backwards & forwards with clasped fingers of right hand in left palm & vice versa
			
9. Do rotational rubbing of left wrist with right hand & vice versa	10. Rinse hands with water	11. Your hands are safe after drying	
			

Figure A1.1 Steps of hand washing
Source: Training of health staff in colposcopy, LEEP and CKC - Trainees’ handbook, World Health Organization,2017

Encourage healthcare staff to get available immunizations, especially Hepatitis B vaccine.

Being vaccinated protects not only healthcare workers but also their fellow workers, clients and families.

2. Decontamination

- Once the colposcopy procedure is completed, contaminated objects including swabs and other waste items need to be disposed in a leak-proof container with a lid assigned for the purpose while wearing the gloves.
- Instruments and other items should be submerged in a container filled with 0.5% chlorine solution for 10 minutes before allowing health staff and/or cleaning personnel to handle or clean it.
- Before submerging assembled needles and syringes, fill the container with chlorine solution (This step is necessary to prevent transmission of HBV and HIV/AIDS to clinic staff).
- Wipe all surfaces with 0.5% chlorine solution or 60-90% Ethyl or Isopropyl alcohol or Iodophores to prevent transmission of infection from one patient to another or to healthcare providers (eg: cryotherapy unit, focusing lamp, Colposcope, patient examination table, instrument stand, floor of the screening clinic which could have been contaminated with blood or other body fluids).
- Both gloved hands should be immersed in a bucket containing 0.5% chlorine solution and then carefully remove gloves by turning them inside out. If disposable gloves were used, dispose them in a leak - proof container or plastic bag. If reusable gloves were used, they should be submerged in a chlorine solution for 10 minutes for decontamination.

3. Cleaning

Cleaning will reduce the number of microorganisms (including bacterial endospores).

It is necessary to wear utility gloves to clean. Scrub the instruments with detergent and rinse thoroughly with water.

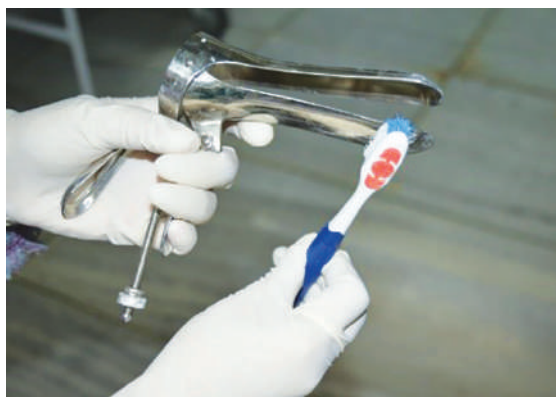

Figure A1.2 Cleaning by scrubbing with brush

Source: Training of health staff in colposcopy, LEEP and CKC - Trainees' handbook, World Health Organization, 2017

4. Sterilization

- Sterilization or high-level disinfection.
 - Steam sterilization - 121°C (250°F)
Unwrapped items - 20 minutes
Wrapped items - 30 minutes
Dry all items thoroughly before removing
 - Surgical (metal) instruments and surgical gloves should be steamed or boiled for 20 minutes and allowed to dry.
 - Instruments can be soaked for 20 minutes in 0.1% chlorine solution prepared with boiled water and air dried.
- Use immediately or store for up to 1 week in a dry, high-level disinfected container with a tight-fitting lid or cover.

5. Methods of processing instruments

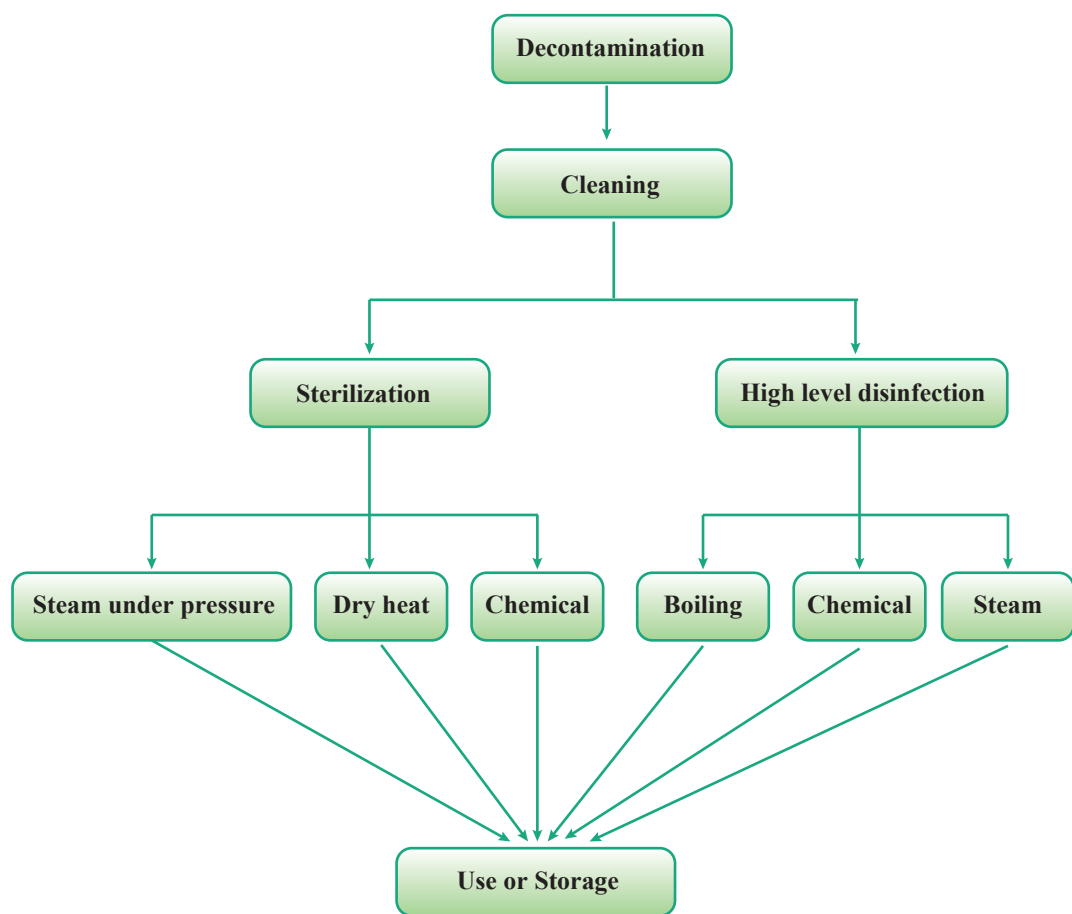


Figure A1.3 Methods of processing instruments

Source: *Training of health staff in colposcopy, LEEP and CKC - Trainees' handbook*, World Health Organization, 2017

6. Processing of instruments

Instruments/Consumables	Process Required	Suggested Procedures
Vaginal speculum, biopsy forceps, endocervical curette, endocervical speculum, vulsellum forceps, insulated speculum, vaginal side-wall retractor	Decontamination, cleaning followed by sterilization or HLD	Autoclaving or HLD by boiling
Gloves	Decontamination, cleaning followed by sterilization	Autoclaving in wrapped packs
Colposcope, LEEP equipment, cryotherapy equipment, cryo gas cylinder, Cold coagulator with probe, examination table, halogen lamp, instrument trolley	Decontamination	Wipe with ethyl alcohol
Cryotherapy probes	Decontamination, cleaning followed by HLD	Disinfection with 0.1% chlorine or 2% glutaraldehyde

Table A1.1 Processing of instruments
Source: *Training of health staff in colposcopy, LEEP and CKC - Trainees' handbook*, World Health Organization, 2017

7. Measures to be taken if exposure occurs

When exposure to blood or other body fluids occur, following steps should be adhered to reduce the risk of infection with HBV, HIV and other blood-borne pathogens.

- If exposure to skin or mucous membranes occurs, wash the affected area immediately with soap and water and rinse thoroughly to remove any potentially infectious particles.
- When a puncture wound or cut occurs, allow it to bleed. Cleanse and rinse the wound with soap and water. (Irrigating with saline, alcohol or iodine has not been shown to decrease risk of infection with HBV or HIV and may even result in irritation and scarring).
- Flush the eye immediately with water, then irrigate for 30 minutes with normal saline if exposure to eye occurs.

Healthcare workers should be made aware about the treatment options, so that they can make informed choice whenever they are exposed to blood or body fluids. An antiretroviral agent, such as Zidovudine (ZDV or AZT) should be offered if available within 1–2 hours after exposures with the highest risk of transmission. Further, they should be aware of which antiretroviral agents are available locally and how to obtain them.

ANNEX II

PERPARATION OF SOLUTIONS

1. Preparation of dilute Acetic acid

► Ingredients

- Glacial acetic acid – 5 ml
- Distilled water – 95 ml

► Apparatus & consumables

- Graduated measuring cylinder (capacity 100 ml)
- Glass container for storage
- Pair of gloves
- Syringe

Steps of preparation

Wear gloves	Measure 5 ml of glacial acetic acid	Pour acetic acid in measuring cylinder
		
Add 95ml of distilled water	Pour prepared acetic acid in glass bottle	Label along with date of preparation
		








Figure A2.1 Steps of preparation of dilute Acetic acid
Source: Training of health staff in colposcopy, LEEP and CKC - Trainees’ handbook, World Health Organization,2017

2. Preparation of Lugol’s Iodine

Materials required (For preparation of 100 ml of Lugol’s Iodine)

- **Ingredients**
 - Potassium iodide 10g
 - Distilled water 100ml
 - Iodine crystals 5 g
- **Apparatus & consumables**
 - Electronic top pan balance
 - Measuring cylinder
 - Glass beaker
 - Glass stick
 - Amber coloured glass bottle
 - Filter paper

Steps of preparation

Wear gloves	Measure 10gm KI	Dissolve 10 g KI in 100ml distilled water
		
Add 5 gm Iodine crystals to the solution	Stir to dissolve Iodine crystals	Filter the solution
		
Pour filtered solution in amber coloured bottle, label and store		
		
Figure A2.2 Steps of preparation of Lugol's Iodine <i>Source: Training of health staff in colposcopy, LEEP and CKC - Trainees' handbook, World Health Organization, 2017</i>		

3. Preparation of Chlorine solution

Materials required

For preparing 1 liter of 0.5% Chlorine solution

- Plastic bucket (medium size) and mug
- Wooden stirrer
- Tea spoon
- Bleaching powder kept in air tight container
- Water
- Utility gloves & lab apron

Calculation of required amount of household bleach

- Grams/lit = [% of dilute solution/% of concentrate of active ingredient (Calcium Hypochlorite) of dry powder] X 1000
- E.g. To make 0.5% chlorine solution from 35% of Calcium Hypochlorite powder
- [0.5%/35%] X 1000 = 14.2 grams of dry powder will be required to prepare 1 liter of solution

Steps of preparation









Wear utility gloves	Take 1 liter water in a plastic bucket	Measure bleaching powder: 14.2 g
		
Add little water to bleaching powder & mix with stirrer to make a thick paste	Add this paste to the water in bucket	Stir till a milky white solution is ready
 		
Label with date of preparation	Caution <ul style="list-style-type: none"> Prepare Chlorine solution daily as it loses strength over time Use clean water (free of organic matters) for preparation of solution Prepare the solution in a well -ventilated area Wear gloves and laboratory apron to avoid direct contact of chlorine solution with skin Use plastic containers for preparation and storage 	
		

Figure A2.3 Steps of preparation of Chlorine solution

Source: Training of health staff in colposcopy, LEEP and CKC - Trainees’ handbook, World Health Organization,2017

4. Preparation of Monsel's paste

- Ferric sulphate base: 15 gm
- Ferrous sulphate powder: few grains
- Sterile water for mixing: 10 ml
- Glycerol starch: 12 gm
- Electronic top pan balance
- Measuring cylinder
- Mortar and pestle
- Glass beaker
- Glass stick
- Brown glass bottle
- Laboratory apron

Preparation

1. Pour 10 ml of sterile water into a glass beaker and add few grains of ferrous sulphate powder and shake
2. Mix the solution with a glass stick until it becomes crystal clear
3. Weigh the glycerol starch in a glass mortar and mix well
4. Add ferric sulfate solution slowly to glycerol starch while mixing it constantly until it becomes a homogeneous solution
5. Place it in a 25 ml brown glass bottle
6. Enough evaporation is needed for the solution to become a sticky paste like consistency that looks like mustard. This will take about 2 -3 weeks depending on the environment. The container then be secured for storage. If the paste is too thick, make it thin by adding sterile water.
7. Label the container as 'Monsel's paste and for external use only and use by (date)'
8. Once prepared, can be used for 6 months

5. Maintenance of the Colposcope

The Colposcope needs proper care and maintenance

- In order to prevent dust accumulation, cover the Colposcope after use each day (specially the optics and lens).
- Lens need to be cleaned only if necessary, using a soft and clean tissue paper.
- Fiberoptic light cables need to be protected from trauma, twisting or bending to prevent breaking of encased glass strands.
- Light bulbs and fuse need to be replaced as necessary, always keep spares handy.
- Once the clinic is over, Colposcope needs to be decontaminated, use safe disinfectant to remove potentially infected secretions and blood by wiping the portions of the Colposcope that comes in close contact with clinicians. Avoid disinfectant liquids going in to the optics.
- At least once a year, the machine should be serviced by a trained clinician.

ANNEX III

Management of screen positive women based on colposcopy and histopathology diagnosis

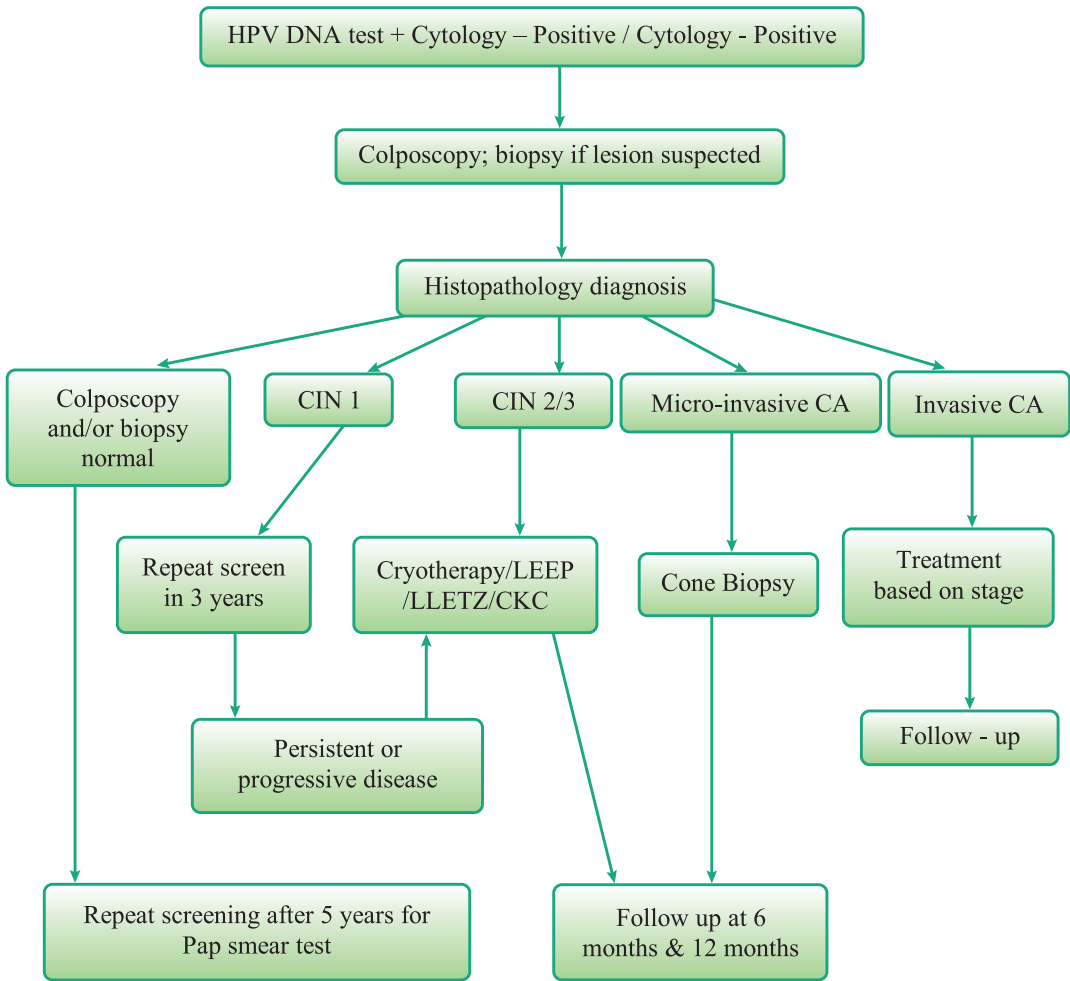


Figure A3.1 Management of screen positive women based on colposcopy and histopathology diagnosis
Source: Training of health staff in colposcopy, LEEP and CKC - Trainees' handbook, World Health Organization, 2017

REFERENCES

1. Training of health staff in colposcopy, LEEP and CKC - Trainees' handbook. New Delhi: World Health Organization, Regional Office for South-East Asia; 2017. License: CC BY-NC-SA 3.0 IGO.
2. Cancer Incidence Data Sri Lanka 2011. Colombo: National Cancer Control Programme; 2018.
3. National Cancer Incidence and Mortality Data Sri Lanka 2012. Colombo: National Cancer Control Programme; 2020.
4. National Strategic Plan 2019 - 2023 Well Woman Programme. Colombo: Family Health Bureau, Ministry of Health, Sri Lanka; 2019.
5. Ferlay et al., Global Cancer Observatory [Internet]. Globocan.iarc.fr. 2012. Available from: <http://globocan.iarc.fr>.
6. Guidelines for cervical cytology screening and reporting in Sri Lanka [Internet]. Google Docs. 2010. Available from: <https://drive.google.com/file/d/1saAhz4gSnUHxYryCKRoxGtc2uBBRGst/view>
7. Bird EM, Clin Microbiol Rev, Solomon D, et al. [Internet]. Vacfa.uct.ac.za. 2003. Available from: http://www.vacfa.uct.ac.za/sites/default/files/image_tool/images/210/AAVC2010-lecture-slides/AAVC-2014-day-2/AAVC-2014-day-3/HPV%20vaccination%20VACFA%202014.pdf
8. Soutter W, de Barros Lopes A, Fletcher A, Monaghan J, Duncan I, Paraskevaidis E et al. Invasive cervical cancer after conservative therapy for cervical intraepithelial neoplasia. The Lancet. 1997;349(9057):978-980.
9. Soutter W, Sasieni P, Panoskaltsis T. Long-term risk of invasive cervical cancer after treatment of squamous cervical intraepithelial neoplasia. International Journal of Cancer. 2006;118(8):2048-2055.
10. Ghaem-Maghami S, Sagi S, Majeed G, Soutter W. Incomplete excision of cervical intraepithelial neoplasia and risk of treatment failure: a meta-analysis. The Lancet Oncology. 2007;8(11):985-993.
11. Khalid S, Carcopino X, Michail G, Metchette S, Conroy R, Prendiville W. Compliance with follow up cytology after discharge from the colposcopy clinic. Ir Med J. 2011;104(6): 167-70.